



# **BRAIN INSULT:**


## **You Are a Piece of The Puzzle**

Spencer D. Johnson, OD, FAAO

Kelly A. Malloy, OD, FAAO, Diplomate

Katherine K. Weise, OD, MBA, FAAO





Spencer D. Johnson, OD, FAAO  
1800 S Novell Place  
Provo, UT 84606  
[spencer.johnson@rm.edu](mailto:spencer.johnson@rm.edu)

The content of this COPE Accredited CE activity was prepared independently by Dr. Johnson.

Dr. Johnson has no direct financial or proprietary interest in any companies, products, or services mentioned in this presentation.  
The content and format of this course is presented without commercial bias and does not claim superiority of any commercial product or service.





Kelly A. Malloy, OD, FAAO, Diplomate  
1200 W. Godfrey Avenue  
Philadelphia, PA 19141

*Dr. Malloy is a consultant and speaker for Osmotica Pharmaceuticals and RVL Pharmaceuticals, which has no association with anything in this lecture.*

The content of this COPE Accredited CE activity was prepared independently by Dr. Malloy.

Dr. Malloy has no direct financial or proprietary interest in any companies, products, or services mentioned in this presentation.

The content and format of this course is presented without commercial bias and does not claim superiority of any commercial product or service.





UAB THE UNIVERSITY OF ALABAMA AT BIRMINGHAM

Katherine K. Weise, OD, MBA, FAAO

1716 University Blvd  
Birmingham, AL 35233  
kweise@uab.edu



Dr. Weise is the lead team physician for vision within UAB Sports and Exercise Medicine. She is a professor of optometry and the Director of the UAB Eye Care Pediatric Optometry Service.

In addition to the NCAA Division I athletes, she is a primary referral source of Children's of Alabama Concussion Clinic.

The content of this COPE Accredited CE activity was prepared independently by Dr. Weise.

Dr. Weise has no direct financial or proprietary interest in any companies, products, or services mentioned in this presentation.

The content and format of this course is presented without commercial bias and does not claim superiority of any commercial product or service.







# What are your possible “puzzle pieces”

- Identify that a brain insult is present
  - History and exam
- Help diagnose the etiology of the brain insult
  - Imaging sometimes needed
- Arrange for the patient to get any medical / specialist care that they need
  - ED vs outpatient referral
- Rehabilitation
  - Glasses, VT, prisms, etc





# Acquired Brain Injury

THIS TERM IS MISLEADING

## **ACQUIRED**

A person can be born with brain injury

They would still need services to help them function, even though they do not have ACQUIRED brain injury

## **BRAIN**

Can be damage to brain but also spinal cord

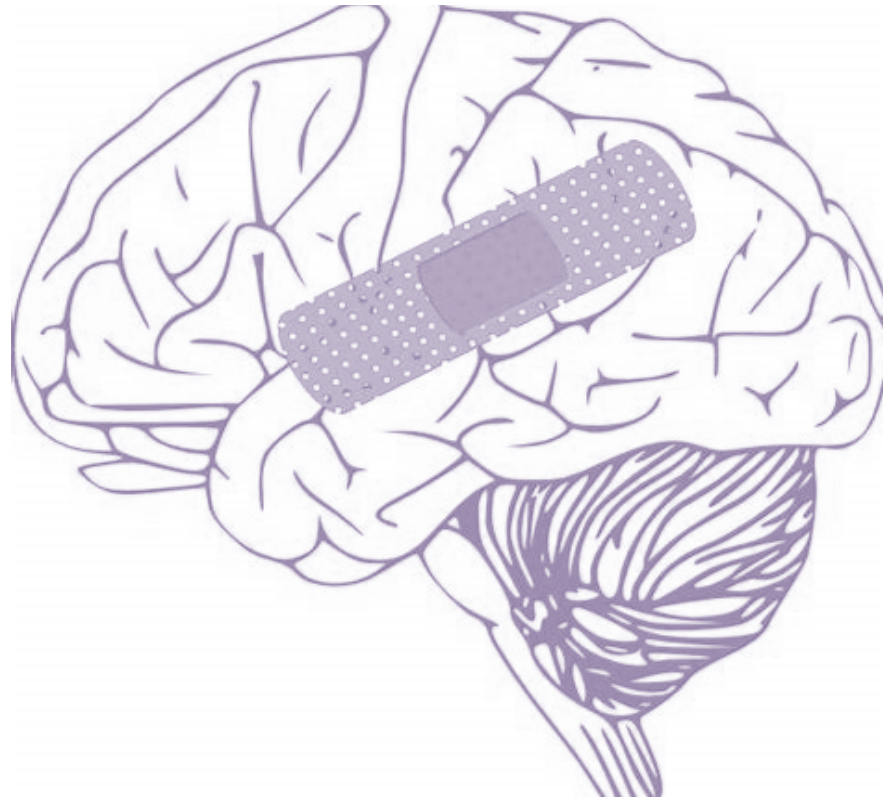
## **INJURY**

This makes it sound like it has to be from external trauma  
It really can be any type of damage, either traumatic or non-traumatic, and from either an external or internal source



- So, a better way to think about it is:

**ANY NEUROLOGIC DAMAGE**





# 4 Main Categories of Brain Insult

- Traumatic Brain Injury
- Tumor
- Stroke
- Neurodegenerative Disease

We will go through a case of each of these.



# There are other, less common causes

- Infection
- Poisoning
- Hypoxia
- Encephalopathy
- Substance Abuse
- ...



# No 2 Brain Insults are Alike

- Patient's experiences are unique depending on many factors
  - Nature of the injury/damage
  - Severity of the injury/damage
  - Exact anatomic location of the injury/damage
  - Effects of the ABI
    - Physical
    - Intellectual
    - Behavioral
    - Social
    - Emotional

Patients will need the proper team of providers to help with these effects.

We are part of that team!



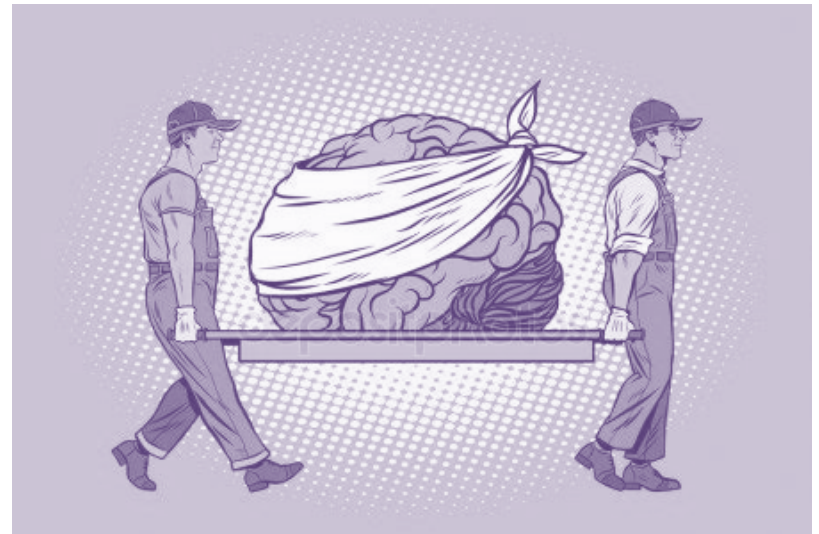



# One thing ALL brain insults have in common

---

- Some part of a person's life will be ADVERSELY AFFECTED
- Life adjustments (major or minor) will now be needed
- Recovery is dependent on rapid identification, treatment and rehabilitation





# Patients will present differently

Sometimes, the patient will present knowing something happened (trauma).

However, other times, they just have some visual complaints, and you will have to determine that there is brain insult.





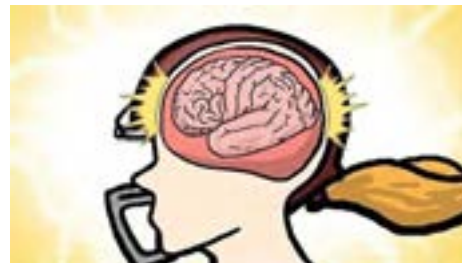
# TBI Background Information





# TBI

- Most common in varying age groups
  - 1. Older adults (>75 years)
  - 2. Very young (0-4 years)
  - 3. Young adults (15-24 years)
    - Sports injury a common cause in adolescents



## The most common causes of TBI:

1. **FALLS** in the older population
2. Being struck by an object
3. Motor vehicle accidents



# TRAUMATIC BRAIN INJURY (TBI)

- CLASSIFICATION USING GLASCOW COMA SCALE (GCS)

- MILD (GCS score of 13-15)
- MODERATE (GCS score of 9-12)
- SEVERE (GCS score of <8)

- Mild TBI is usually due to contact or acceleration /deceleration forces
- Concussion is often used to identify mild TBI

**Glasgow Coma Scale**

BEHAVIOR	RESPONSE	SCORE
Eye opening response	Spontaneously	4
	To speech	3
	To pain	2
	No response	1
Best verbal response	Oriented to time, place, and person	5
	Confused	4
	Inappropriate words	3
	Incomprehensible sounds	2
	No response	1
Best motor response	Obeys commands	6
	Moves to localized pain	5
	Flexion withdrawal from pain	4
	Abnormal flexion (decorticate)	3
	Abnormal extension (decerebrate)	2
	No response	1
Total score:	<i>Best response</i>	15
	<i>Comatose client</i>	8 or less
	<i>Totally unresponsive</i>	3



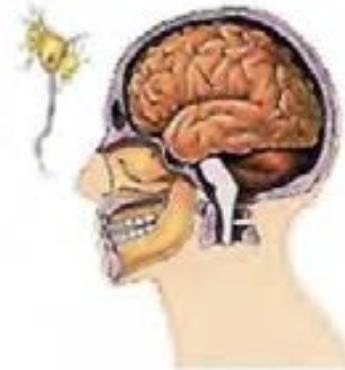

# CONCUSSION

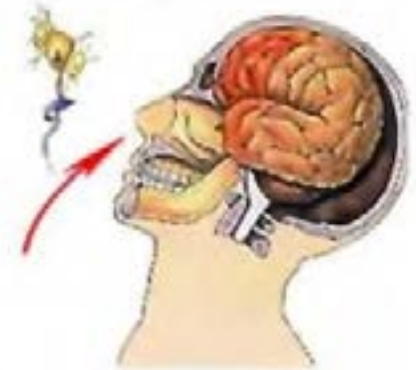- Trauma-induced alteration in mental status that may or may not involve loss of consciousness



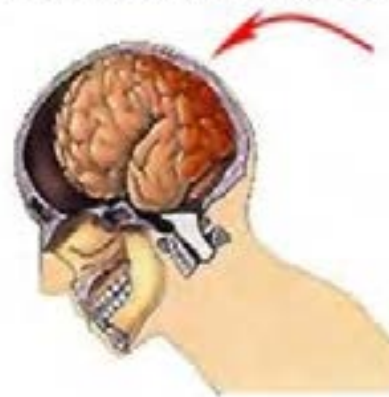Before impact



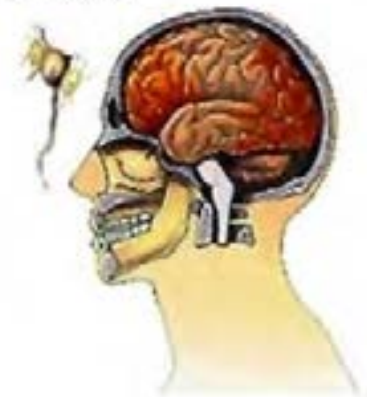
Initial impact: Coup



Secondary impact: Contre-coup



Post-injury







# Mild Traumatic Brain Injury (mTBI)

- An acute brain injury resulting from mechanical energy to the head from external physical forces.
- **Concussion = mild TBI**
- Can be associated with confusion, amnesia, and loss of consciousness
- **Does not have to have associated loss of consciousness**



## TBI Symptoms / Post-Concussion Syndrome

- Eyestrain
- Headache
- Blur
- Diplopia
- Loss of concentration
- Sleepiness
- Dizziness
- Balance Issues
- Light Sensitivity
- Noise Sensitivity
- Anxiety
- Depression
- Difficulty Making Decisions
- Sleep Disturbance

Although most symptoms will resolve with time, 15% of mTBI patients have disabling symptoms after 1 year!



# SLEEP DISTURBANCES IN TBI

- Seen in ALL classifications of TBI
- Excessive daytime sleepiness
- Increased sleep need
- Insomnia
- Sleep fragmentation



# TBI and VISUAL SYMPTOMS

- visual symptoms occur in MOST (75%) individuals with concussion
- blurred vision, poor visual focus, difficult reading, diplopia, rarely shaking vision (i.e., oscillopsia), photophobia, intolerance of visual activities, headaches, and dizziness.
- Poor tolerance of visual activities such as screen use and scrolling on smart phones is common

# Concussion and Vision Literature in Children

## Prevalence Studies: Signs

Study	N	Ave. age	Study Design	Conv Insuff	Accomm Insuff	Eye Tracking	Visual Field	Specialty if not Eye Care
<b>Master C Scheiman M 2016</b>	<b>100</b>	<b>14.5</b>	<b>pro</b>	<b>49%</b>	<b>51%</b>	<b>29%</b>		
<b>Pearce KL 2015</b>	<b>78</b>	<b>14</b>	<b>pro</b>	<b>42%</b>				Ortho
Stelmack 2009	103		retro	28%	47%	6%	14%	
Brahm 2009	191		retro	42%	42%	33%	32%	
Goodrich 2007	50		retro	30%	22%	20%	21%	Psychology
Suchoff 1999	62	19-70		42%	10%	40%	32%	
<b>Normal population</b>				<b>BV = 5%</b>	<b>3%</b>	<b>2%</b>		



# CASE 1

## TBI





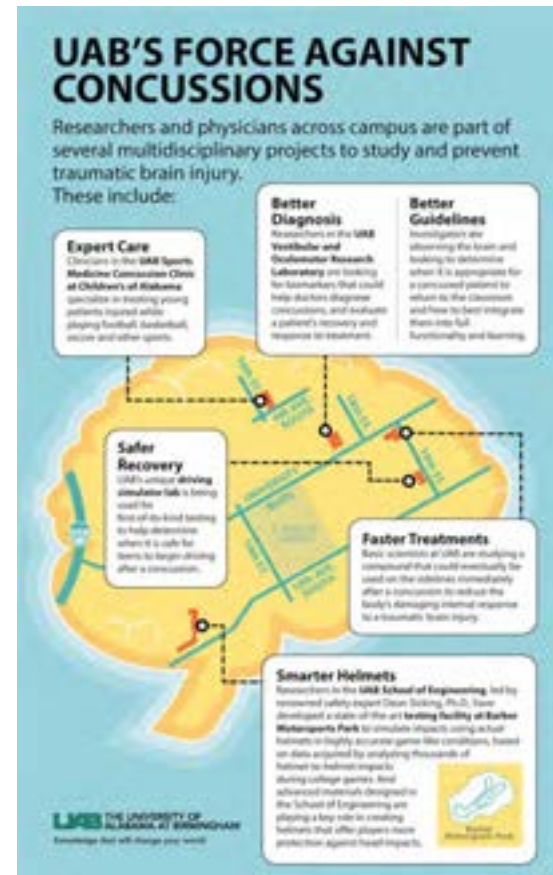


14 yo beautiful WF with strong mama  
and with history of concussion





# What do you want to know about referral source?



1. ATC/Coach
2. Pediatrician
3. Team Physician
4. Neurologist
5. Neuropsych
6. Peds Rehab
7. Parent





# What do you want to know about referral source?

1. Who

2. Where

3. When

4. Who's driving the bus?



# What do you want to know about the injury?

- Date of injury
- Loss of consciousness
- Event amnesia
- How many concussions prior?
- MRI or CT?





# What symptoms (visual or general) might she have?

- Dizziness
- loss of concentration
- brain fog
- academic difficulty
- Imbalance
- Vertigo
- Not herself
- Headaches
- Sleep issues
- Photophobia
- Difficulty switching from board to desk
- “Grocery store” (high school hallway) syndrome
  - VMS on VOMS (eyes look at thumbs; torso turns back and forth in front of busy background)





# What do you want to ask about school?

- Full time? Part time? At home?
- Passive? Active learning? Tests?
  - “Sponge learning”
- After school activities?
- Return to play?
- Accommodations (large print, sunglasses, leave class early, water at desk, reader/aide, earplugs, fewer items on page, no devices, double-sided copies, no devices)







# What other systemic conditions might go along with concussion?

- ADD/ADHD,
- depression,
- Anxiety



Something to consider:  
Concussion may be less likely to  
*cause* these and more likely that it  
*lowers tolerance.*



# Can you think of any other questions to consider?

- 1. Other doctors?
  - Vestibular
  - Vision
  - PT
  - Counseling
  - Audiology
- 2. Who's driving the bus? Who's overseeing all care?
- 3. Getting better or worse?
- 4. Scale of 1-100, how old are to your old self?



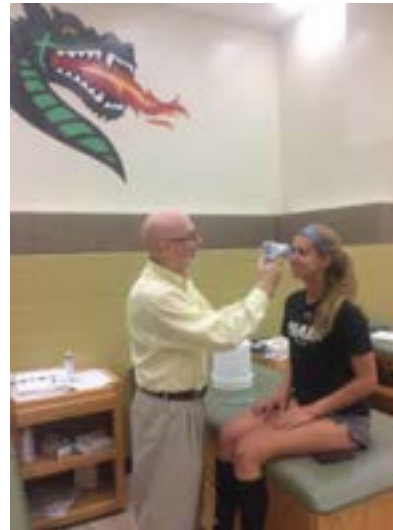# What objective tests do you want to consider that tells us how the eyes are messed up after concussion?

- VA's (PH?)
  - 20/20 OD, OS
- Cover Test
  - 0-1 XP
  - 0-6 XP'
- Ams (age minimums)
- MEM
  - PI to 0.75 D
- Facility
  - +/-2.00 facility
    - (normal ~10-12 cpm)
  - 3 BI/12 BO facility
    - (normal ~15 cpm)
- NRA/PRA
  - +2.50/-2.50
- Vergences
  - Double demand/Cover Test
- DEM
  - Normative Data
- CISS
  - $\geq 16$  child = symptomatic
  - $\geq 21$  adult = symptomatic
- Refractive error (wet and dry)



What objective tests do you want to consider that tells us how we can use the eyes to tell us about the brain after concussion?

- (DFE? Yes, unless contra indicated...T1-4'-T1)
- CF
- EOM's
- Pupils
  - Pupillometer
- OCT
  - ONH, GCC
- VF
  - 120-point neuro screener
- VOMS or SVV



	Right	Left	Diff
NPI	4.6	4.7	L > R 0.1
Size	5.29 mm	4.62 mm	R > L 0.67
MIN	2.81 mm	2.61 mm	R > L 0.20
CH	47%	44%	
CV	4.21 mm/s	3.94 mm/s	
MCV	6.50 mm/s	5.87 mm/s	
LAT	0.23 sec	0.23 sec	
DV	1.73 mm/s	1.89 mm/s	



# Assessments for our Patient

- Accommodative insufficiency:
  - Difficulty keeping near work clear, which could cause intermittent blur and eye strain
  - 5 D OD, OS: Eyes of a 40 year old
- Accommodative infacility/(vergence infacility)
  - Difficulty switching focus from distance to near to keep things clear (and single)
- Good convergence, good eye tracking, good objective pupil function
- Minimal need for glasses in the absence of concussion
  - +0.50 D, OD, OS
- Subnormal distance visual acuity (20/30 OD, OS)



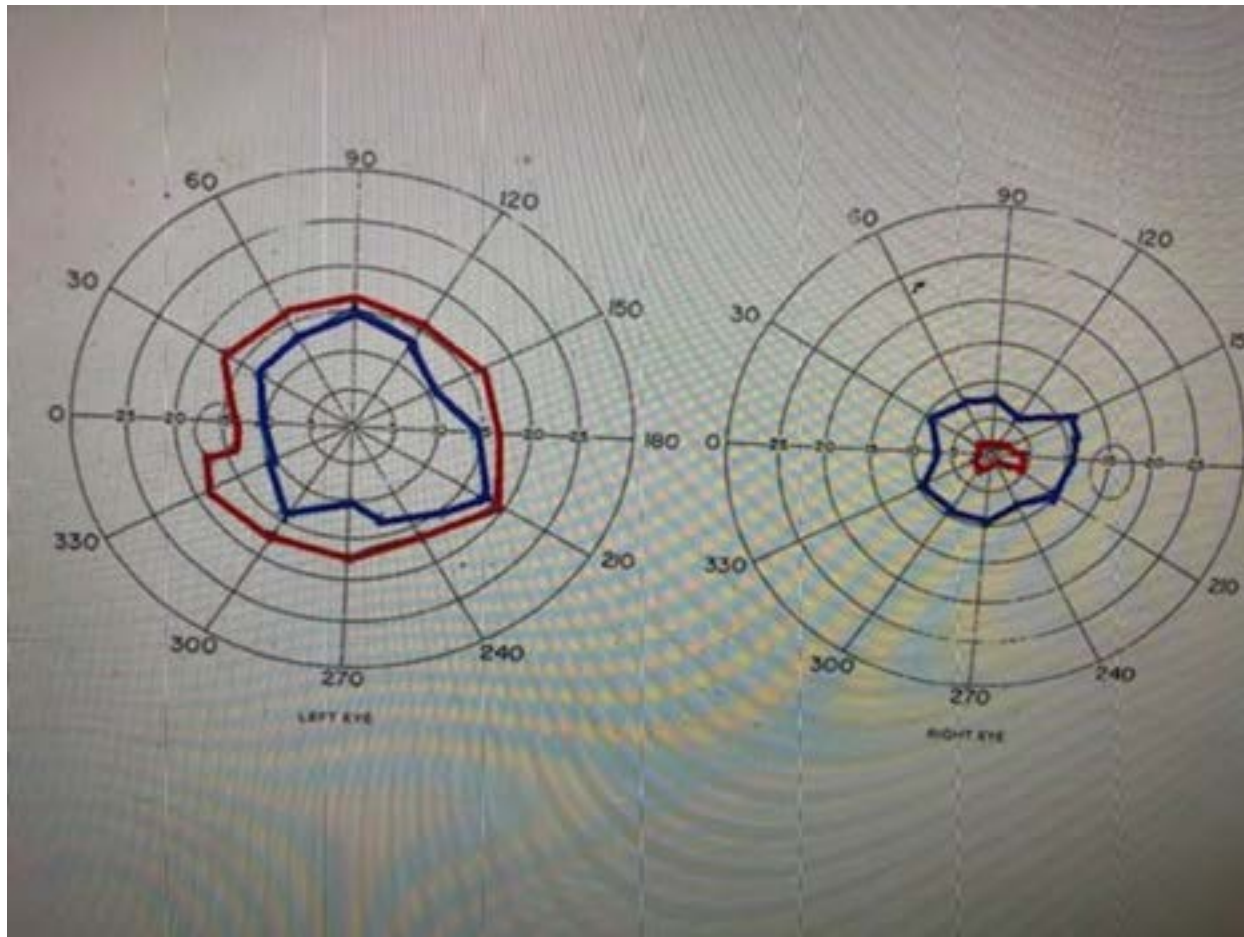
Anterior and posterior seg are normal  
as they typically are; what other  
diagnoses and tests  
should we consider?

- PH
- Tangent screen





# Tangent screen – visit 1





# What's your concern/diagnosis?

- Psychogenic amblyopia
- Conversion reaction
- Functional vision loss



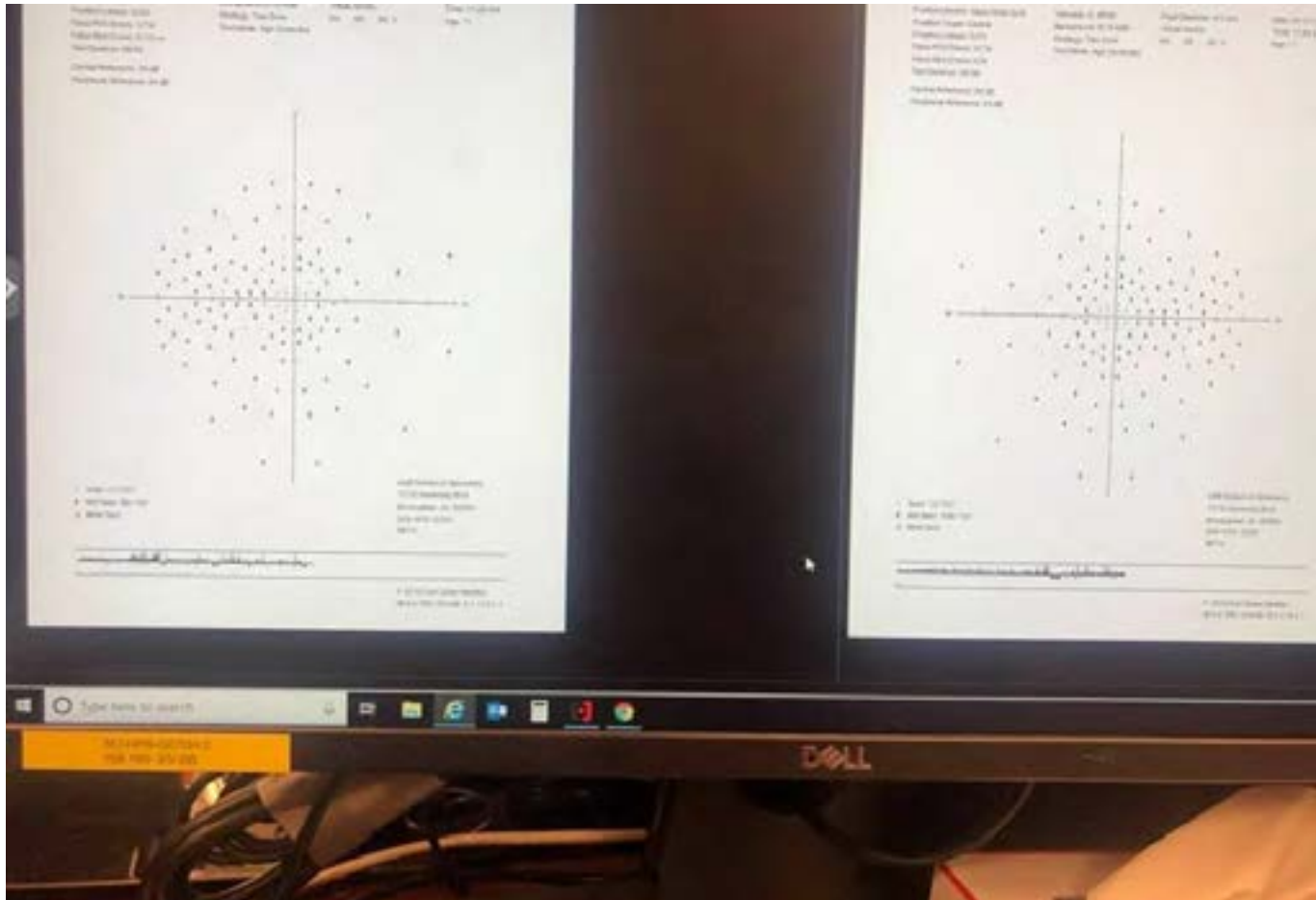




Do you want to see  
120-point screener?



# Do you want to see 120-point screener?





# PANEL DISCUSSION





# What's your added diagnosis?

- Psychogenic amblyopia
- Conversion reaction
- Functional vision loss



# FVL: Peds vs. mTBEye Clinic

Vinogradov H, Weise KK, Swanson MW, et al

- N = 58 (Peds) and 54 (mTBEye)
  - Age: 9 to 17 years
    - Peds: 12.5 (2.3)
    - mTBEye: 12.9 (2.5)



# FVL: Peds vs. mTBEye Clinic

Vinogradov H, Weise KK, Swanson MW, et al

- FVL

- Peds: 1.7% (1/58)
- mTBEye: 16.7% (9/54)
  - VA only: 11.2% (1/9)
  - VF only: 44.4% (4/9)
  - VA + VF: 44.4% (4/9)
  - + Accommodative Spasm: 11.1% (6/54)

**FVL: 27.8% (15/54)**

# What causes FVL?

- Mood disorders?? (Old school)
  - Stress
  - Anxiety
  - Depression
- Or not (new thinking)
  - Espay AJ, Aybek S, Carson A, Edwards MJ, Goldstein LH, Hallett M, LaFaver K, LaFrance WC Jr, Lang AE, Nicholson T, Nielsen G, Reuber M, Voon V, Stone J, Morgante F. Current Concepts in Diagnosis and Treatment of Functional Neurological Disorders. JAMA Neurol. 2018 Sep 1;75(9):1132-1141. doi: 10.1001/jamaneurol.2018.1264. PMID: 29868890; PMCID: PMC7293766.
  - Not all smokers get lung cancer and not all lung cancer is from smoking.
  - Let's go back to the neuro roadways prior to the construction detours.



# What are your management suggestions?

- 1. No glasses to see clearly in the absence of concussion, but perhaps helpful to see more comfortably
  - Anti-fatigues...Hoya Sync 9 or Eyezen3
- 2. Referral for counseling
  - Neuropsych?
  - School counselor?
  - Or Functional Neurological Disorder (FND) expert





# Concussion Management Options

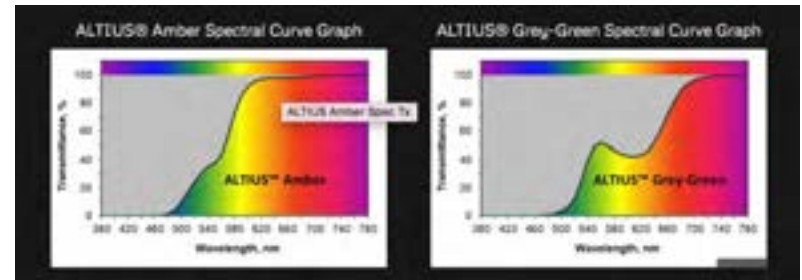
## \_1. Glasses/Contacts

- Normal prescribing patterns +
- Lower hyperopia thresholds
- Adds
  - Anti-fatigues (Hoya or Eyezen) (or readers)
    - SV but shaped like a PAL
    - Low add on bottom (0.5, 0.9, 1.3)
  - OTC Readers?
  - Multi-focal contact lenses?
- Anti-reflective coat = a must

# Concussion Management Options

## 2. Photophobia options

- “Neurophotophobia”
  - ipRGC’s?
  - Trigeminal CN 5?




FL-41 50%

Light Transmittance: 50%



Spectrophotometry Graph



The "Original" CPF Filters		
	<b>CPF® 458 lens</b>	First developed in 1980s
lightened	lightened	Strongly reduce visible light and ultraviolet energy before the designated wavelengths
darkened	darkened	
UVB blockage	UVB blockage	
100%	100%	
	<b>CPF® 511 lens</b>	Tightly controlled light filtering
lightened	lightened	Provides symptomatic relief from glare and fuzzy vision
darkened	darkened	
UVB blockage	UVB blockage	Permanent photochromic performance for use under both natural and artificial lighting conditions
100%	100%	Maximizes remaining vision of patients with various ocular pathologies
	<b>CPF® 527 lens</b>	
lightened	lightened	Fast adaptation means no switching lenses when light level changes
darkened	darkened	
UVB blockage	UVB blockage	
100%	100%	
	<b>CPF® 550 lens</b>	
lightened	lightened	Maximum glare protection
darkened	darkened	
UVB blockage	UVB blockage	Very specialized filter for patients with extreme light sensitivity
100%	100%	
	<b>CPF® 550RD lens</b>	
lightened	lightened	
darkened	darkened	
UVB blockage	UVB blockage	
100%	100%	





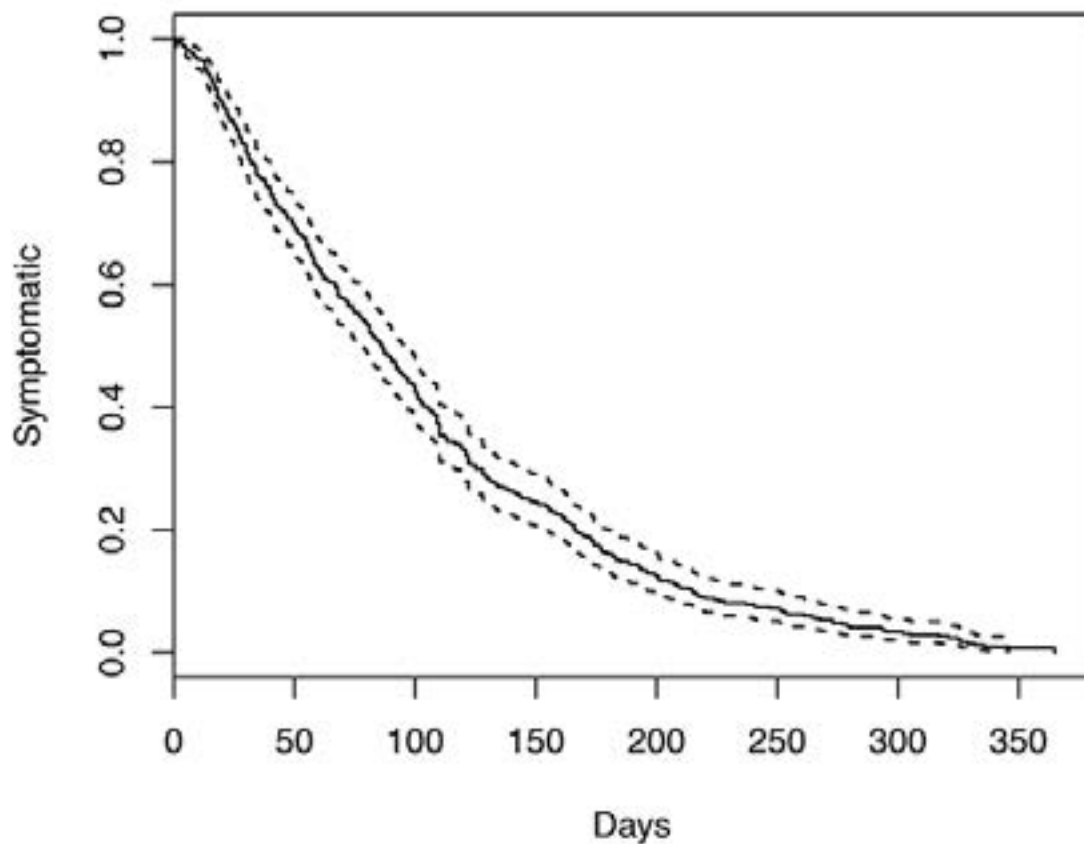
# Concussion Management Options

- 
- 3. VT
- 4. Vestibular referral
  - VOMS abnormal or high CISS with minimal clinical findings
- 5. Classroom adjustments
- 6. Other referrals



Master CL, Master SR, Wiebe DJ, Storey EP, Lockyer JE, Podolak OE, Grady MF. Vision and Vestibular System Dysfunction Predicts Prolonged Concussion Recovery in Children. Clin J Sport Med. 2018 Mar;28(2):139-145.

### Time to Recovery, Full Cohort





# 3 Most Common Visual Problems Associated with mild TBI

- **Convergence Insufficiency**
- **Accommodative Dysfunction**
- **Oculomotor Dysfunction**

The midbrain is the center for convergence. The rostral midbrain is known to be highly biomechanically susceptible to injury from head impacts.

CI has been reported in more than half of individuals with concussion.

Convergence insufficiency is the most common ocular motor finding in concussion.

CI has been associated with higher overall concussion symptom burdens and longer recovery times.



# Convergence Abnormalities in TBI

- After TBI, there can be not only convergence insufficiency, but also abnormal **convergence endurance**
  - Can initially read, but difficulty sustaining convergence
  - Difficulty with prolonged reading



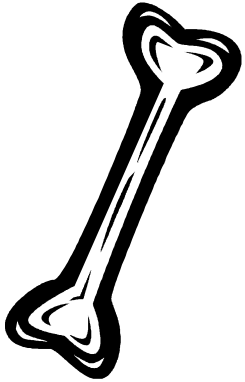
# Imaging for Head Trauma

- Computed Tomography (CT) imaging is the first-line imaging in head injury:
  - CT has higher spatial resolution than MRI
  - CT is more sensitive than MRI for the evaluation of the osseous calvarium, provides exceptional sensitivity for hemorrhage, and makes possible the detection of foreign objects inside the calvarium that would preclude MRI
  - CT is also cheaper, more readily available, and much faster than MRI



# CT for Head Trauma

- Superior to MRI for the following (and contrast not indicated):



Bony Injury

**B**ONE



Acute Hemorrhage

**B**LOOD



Localization of  
Foreign Bodies

**B**B





# Neuroimaging for Concussion

- Only recommend in the setting of suspected concussion in those patients who have:
  - loss of consciousness
  - posttraumatic amnesia
  - persistent Glasgow Coma Scale <15
  - focal neurologic deficit
  - evidence of skull fracture on examination
  - signs of clinical deterioration



# Pathologic Injuries in TBI

(more moderate to severe)

- Skull fracture
- Epidural hematoma
- Subdural hematoma
- Subarachnoid hemorrhage
- Intraparenchymal hemorrhage
- Cerebral contusion
- Intraventricular hemorrhage
- Focal or diffuse patterns of axonal injury with cerebral edema

If imaging not done or initially normal, and symptoms worsen, patient needs imaging to rule out subdural hematoma, which may not have been seen on initial imaging.



# In Outpatient Setting – mainly mTBI

- Most patients exhibit a normal eye exam, despite of their visual complaints.
- There is a suspicion that higher order visual-cognitive functions have become impaired due to diffuse axonopathy causing deficits in connectivity between visual and cognitive areas of the brain.
- The difficulty in identifying the source of visual complaints underscores the diagnostic and treatment dilemma facing healthcare providers, rehabilitation specialists, employers, teachers, athletic administrators and patients.

This is even more difficult to diagnose when there is an overlying functional component.



# POST-TRAUMATIC CRANIAL NERVE INJURY

- Cranial nerve palsies may occur secondary to trauma
- The most common cause of a CN IV palsy is TRAUMA
  - Anterior medullary velum
  - Ambient cistern
  - Free edge of tentorium
  - Trochlea
- Any CN Palsy may occur due to trauma



# POST-TRAUMATIC VERTIGO AND DIZZINESS (can present with nystagmus)

- Substantial contributor to disability after mild TBI
- Central Causes
  - Diffuse axonal injury
  - Vestibular migraine
  - Vertebral artery dissection
  - Psychologic factors (anxiety, PTSD, etc)
- Peripheral Causes
  - BPPV (benign paroxysmal positional vertigo)
    - Shearing and displacement of otoconia into semi-circular canal
    - Injury to cochlear or vestibular structures
    - Labyrinthine concussion

May need to refer to neurology, ENT, or to PT for vestibular therapy.



# POST-TRAUMATIC EPILEPSY

- Mild TBI is associated with a 2x increase in risk of epilepsy for 5 years after injury
- 80% of seizures will occur in first 2 years
- Seizures in first week do not count as epilepsy
  - Considered an acute symptomatic event
- Half of seizures will occur in 1<sup>st</sup> year
- PROPHYLACTIC TREATMENT WITH ANTI-SEIZURE MEDICATION DOES NOT PREVENT POST-TRAUMATIC EPILEPSY AND IS NOT RECOMMENDED



# Afferent Visual Biomarkers in TBI

- **STRUCTURAL BIOMARKERS**
  - Thinning of inner retinal layers
  - MRI visual radiations and cortex
- **FUNCTIONAL BIOMARKERS**
  - Pupil light reflex
  - Contrast sensitivity
  - Visual Field
  - ERG, mfERG
  - Functional MRI
- **BIOMARKERS OF LIGHT SENSITIVITY**
  - Photic blink reflex and grimace

Studies have shown progressive worsening of OCT and to a lesser effect, VF and contrast sensitivity after a TBI.



## Original Investigation | Neurology

# Association of Optical Coherence Tomography With Longitudinal Neurodegeneration in Veterans With Chronic Mild Traumatic Brain Injury

Casey S. Gilmore, PhD; Kelvin O. Lim, MD; Mona K. Garvin, PhD; Jui-Kai Wang, PhD; Johannes Ledolter, PhD; Alicia L. Fenske, BA; Carolyn L. Gentz, MA; Julie Nellis, RN, BSN; Michael T. Armstrong, MD; Randy H. Kardon, MD, PhD

## Abstract

**IMPORTANCE** Mild traumatic brain injury (TBI) may predispose individuals to progressive neurodegeneration.

**OBJECTIVE** To identify evidence of neurodegeneration through longitudinal evaluation of changes in retinal layer thickness using optical coherence tomography in veterans with a history of mild TBI.

**DESIGN, SETTING, AND PARTICIPANTS** This longitudinal cohort study evaluated veterans who were receiving services at the Minneapolis Veterans Affairs Health Care System. Symptomatic or mild TBI was diagnosed according to the Mayo TBI Severity Classification System. Participants in the age-matched control group had no history of TBI. Participants with any history or evidence of retinal or optic nerve disease that could affect retinal thickness were excluded. Data analysis was performed from July 2019 to February 2020.

**EXPOSURES** The presence and severity of mild TBI were determined through consensus review of self-report responses during the Minnesota Blast Exposure Screening Tool semistructured interview.

**MAIN OUTCOMES AND MEASURES** Change over time of retinal nerve fiber layer (RNFL) thickness.

**RESULTS** A total of 139 veterans (117 men [84%]; mean [SD] age, 49.9 [11.1] years) were included in the study, 69 in the TBI group and 70 in the control group. Veterans with mild TBI showed

## Key Points

**Question** Do veterans with a history of mild traumatic brain injury show greater neurodegeneration over time compared with control veterans with no history of head injury?

**Findings** In this longitudinal cohort study of 139 veterans with and without a history of mild traumatic brain injury, mild traumatic brain injury was associated with significantly greater thinning of the retinal nerve fiber layer over time.

**Meaning** These findings suggest that structural neural loss in the visual system, as evidenced by thinning of the retinal nerve fiber layer, may be a useful biomarker of neurodegeneration following chronic mild traumatic brain injury.



## Original Investigation | Neurology

## Association of Optical Coherence Tomography With Longitudinal Neurodegeneration in Veterans With Chronic Mild Traumatic Brain Injury

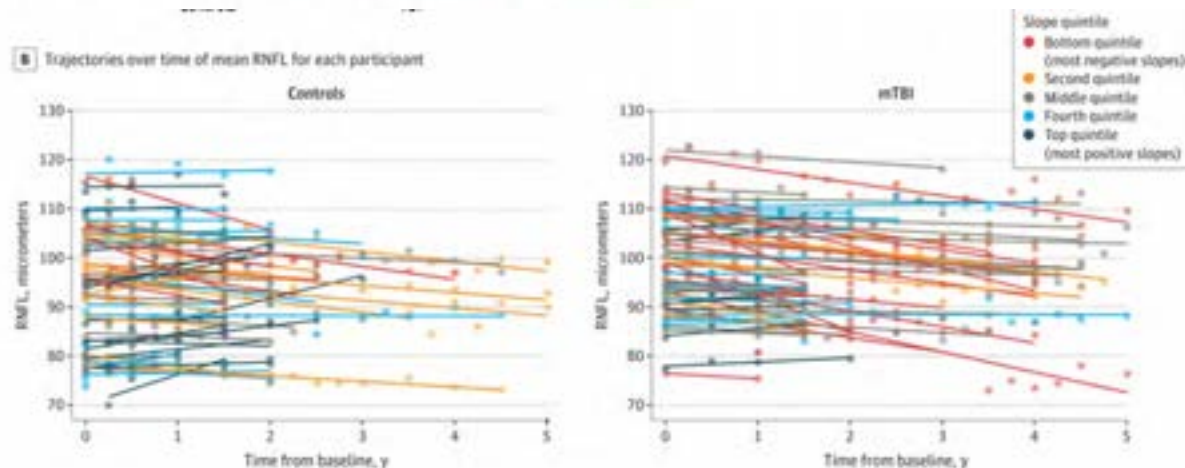
Casey S. Gilmore, PhD; Kelvin O. Lim, MD; Mona K. Garvin, PhD; Jui-Kai Wang, PhD; Johannes Ledolter, PhD; Alicia L. Fenske, BA; Carolyn L. Gentz, MA; Julie Nellis, RN, BSN; Michael T. Armstrong, MD; Randy H. Kardon, MD, PhD



**CONCLUSIONS AND RELEVANCE** This cohort study found longitudinal evidence for significant, progressive neural degeneration over time in veterans with mild TBI, as indicated by greater RNFL tissue loss in patients with mild TBI vs controls, as well as measures of function. These results suggest that these longitudinal measures may be useful biomarkers of neurodegeneration. Changes in this biomarker may provide early detection of subsequent cognitive and functional deficits that may impact veterans' independence and need for care.

JAMA Network Open. 2020;3(12):e2030824. doi:10.1001/jamanetworkopen.2020.30824

Progressive loss of retinal neurons by OCT occurs years after mTBI in veterans.



A, Graph shows mean slope of averaged eyes RNFL (micrometers per year; dark dots with SE bars). Light dots show data for individuals in the mild traumatic brain injury (mTBI) and control groups. Groups significantly differed (mean [SE] RNFL slope,  $-1.47$  [0.24]  $\mu\text{m}/\text{y}$  vs  $-0.31$  [0.32]  $\mu\text{m}/\text{y}$ ;  $F_{1,122} = 8.42$ ;  $P = .004$ , Cohen  $d = 0.52$ ). B, Graphs

show trajectories of RNFL thickness over time for individual participants in mTBI and control groups; dots are time points and lines are linear fit lines for each participant. Colors represent the RNFL slopes grouped by quintiles: bottom quintile contains the most negative slopes, top quintile contains the most positive slopes.



- Those with a history of TBI, including mild TBI (mTBI), are at greater risk for neurodegenerative diseases, such as Alzheimer's Disease (AD), Parkinson's Disease (PD), and Chronic Traumatic Encephalopathy (CTE), even in individuals with no known cognitive impairments after TBI.
- It is suspected that mTBI may initiate a process of persistent neuroinflammation and long-term gray and white matter atrophy leading to progressive neural degeneration over time.



# CHRONIC TRAUMATIC ENCEPHALOPATHY (CTE)

- **Repeated concussions** can cause cumulative neuropsychologic deficits
  - Cognitive impairment
  - Change in behavior and personality
  - Depression
  - Suicidality
  - Parkinsonism
  - Other speech and gait abnormalities

Documented in athletes (boxers, football players) and military personnel (blast injuries).

**Seen in 110/111 deceased NFL players**  
JAMA.  
2017;318(4):360.

But, CTE has been proven to have occurred after just 1 concussion!



# SECOND IMPACT SYNDROME

- Suffering a second traumatic brain injury in close time proximity to a primary brain injury
- Exacerbates neuronal injury in cells made vulnerable by the initial TBI
- Diffuse cerebral swelling develops in the setting of a second concussion, which has occurred when a patient is still symptomatic from an earlier concussion.
- Disordered cerebral autoregulation causing cerebrovascular congestion and malignant cerebral edema with increased intracranial pressure
- Rare, but potentially FATAL

This is why it is so important for an athlete to be immediately removed from play after head trauma!

Athletes will hide symptoms to try to stay in the game.



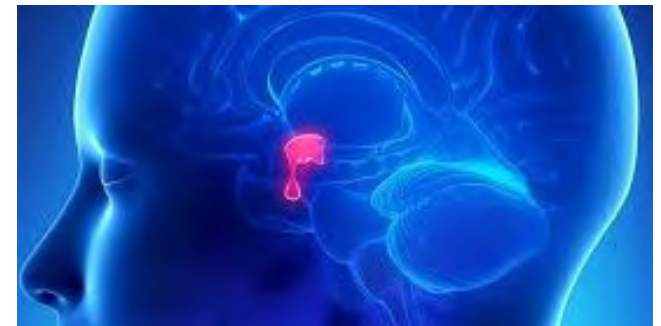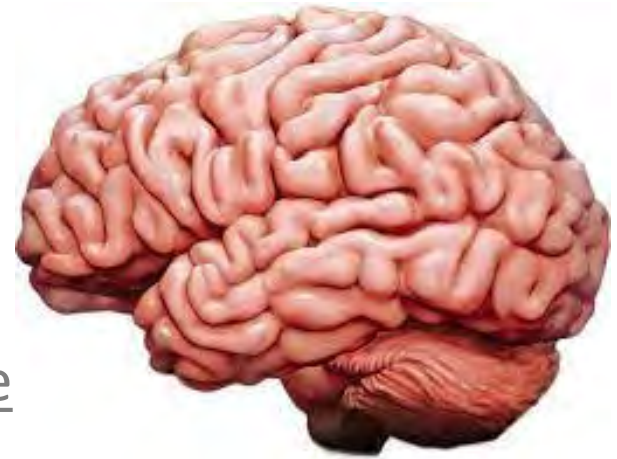# Tumor Background Information





# Tumors Associated with CNS Insult

- Primary Tumors Affecting Brain Tissue
  - Benign
  - Malignant
- Secondary Tumors Affecting Brain Tissue
  - Metastasis to Brain Tissue
  - Metastasis to Bones of Skull
  - Metastasis to CSF
- Tumors of Glands
  - Benign = Adenoma
  - Malignant = Adenocarcinoma





# Basic Types of Primary Cancers

- *Carcinoma* – cancers that are epithelial in origin
  - Lung, Breast, Colon, Prostate, etc. (Often these present as metastatic cancers)
- *Sarcoma* – any cancer of connective tissue or supportive tissue
  - Bone, cartilage, fat, muscle
- *Glioma* – originates in brain or spine tissue
  - Astrocytoma, Oligodendroglioma, Ependymoma
- *Meningiomas* – arise from meninges
  - Atypical, Anaplastic
- *Schwannomas* – nerve sheath / Schwann cells (acoustic neuroma)
- *Medulloblastomas* – a form of primitive neuroectodermal tumor (PNET) in the cerebellum / posterior fossa
- *Hematologic Malignancies* – blood, bone marrow & lymph nodes
  - Leukemia, Lymphoma, Myeloma





# BRAIN METASTASES

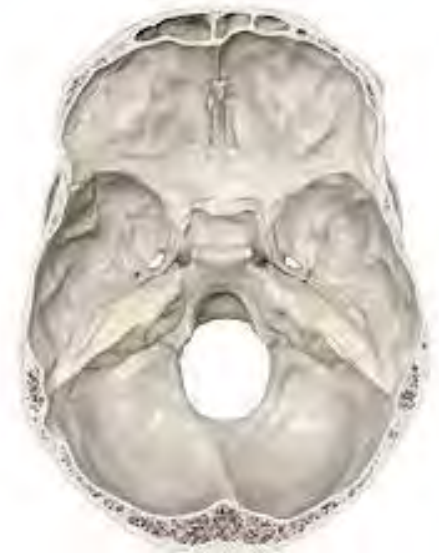- among the most common mass lesions in brain
- increased incidence traced to an increase in the median survival of patients with cancer
  - modern therapies, increased availability of advanced imaging techniques for early detection, and vigilant surveillance protocols for monitoring recurrence
  - most systemic treatments (eg, the use of chemotherapeutic agents, which may penetrate the brain poorly) can transiently weaken the blood-brain barrier (BBB) and allow systemic disease to be seeded in the CNS, leaving the brain a safe haven for tumor growth





# BONE METASTASES

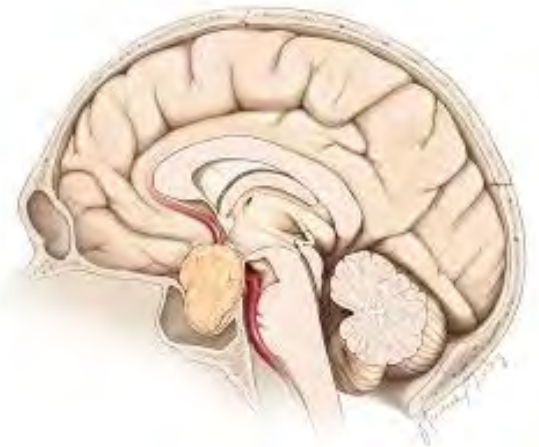- Primary bone cancers are rare
- Associated with lytic lesions and pain
- Sites of Origin
  - Prostate
  - Breast
  - Lung
- Sites of metastases (to cause neuro-ophthalmic disorder)
  - Clivus
  - Skull base





# PITUITARY ADENOMA

- Most common intracranial tumor that optometrists will encounter
- Main concern of mass effect is vision loss
  - Proximity to optic chiasm
- Can be functional or non-functional
  - Endocrine abnormalities
- Can become apoplectic
  - Sudden infarct / bleeding
  - Medical emergency



<https://www.aaroncohen-gadol.com/patients/pituitary-tumor/treatment/surgery>



# CASE 2 TUMOR





# History and Examination

- 41 yo male
- CC: “is noticing that his vision is blurry and gets worse when he has sugars. Is struggling with eye strain while working on the computer at work.”
- Pt. self-reported very low testosterone levels



# History and Examination

## Entering VA cc

OD 20/20++

OS 20/20

## Pupils

OD: PERRLA (-)APD

OS: PERRLA (-)APD

## EOMS

OD: full & smooth

OS: full & smooth

## Confrontation Fields

OD: temporal restriction

OS: temporal restriction



# History and Examination

## IOP

OD: 10 mmHg

OS: 10 mmHg

## Anterior segment

OD: wnl


OS: wnl

## Posterior segment


OD: wnl

OS: wnl

# OD 30-2

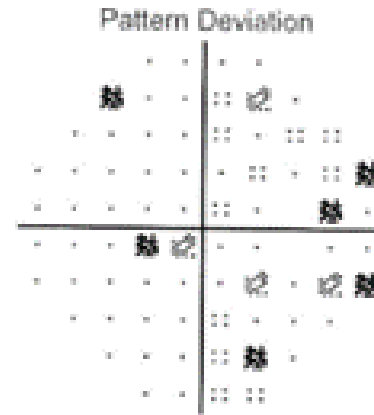
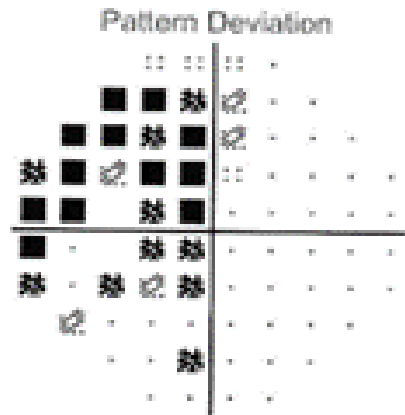


# OS 30-2





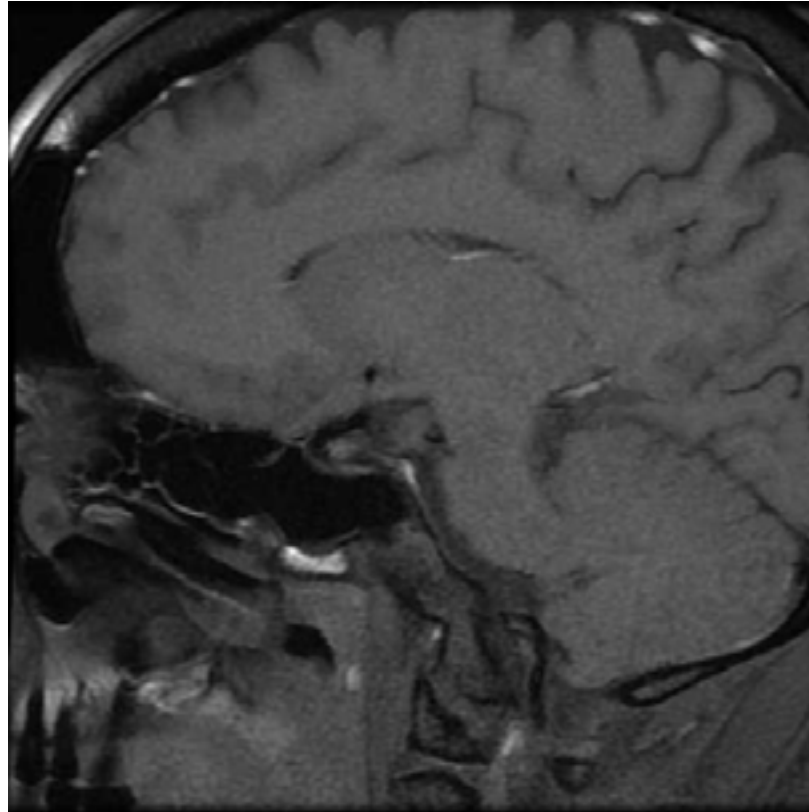
# 30-2 OS and OD

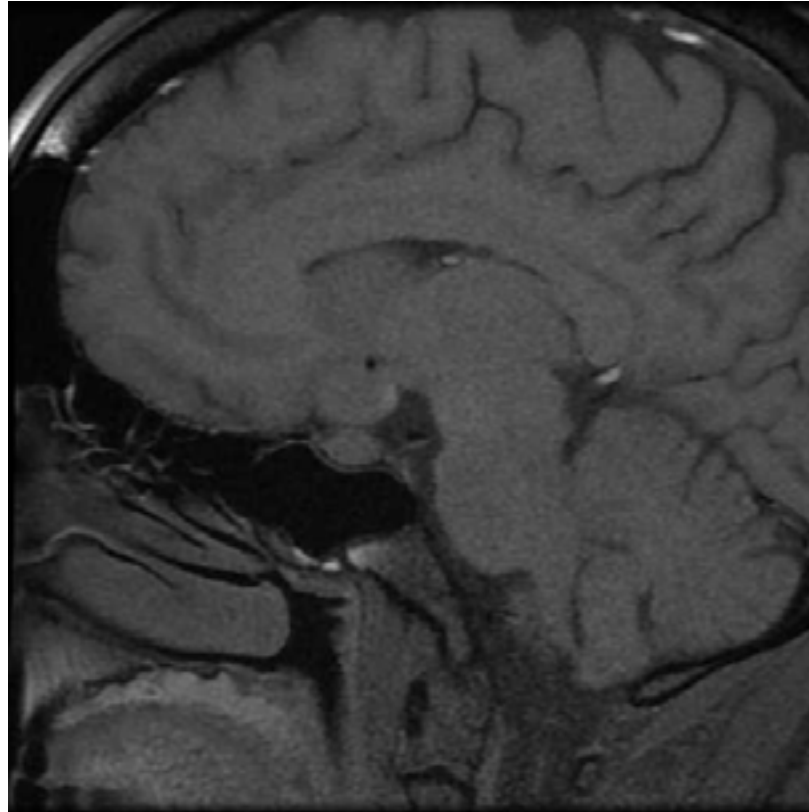


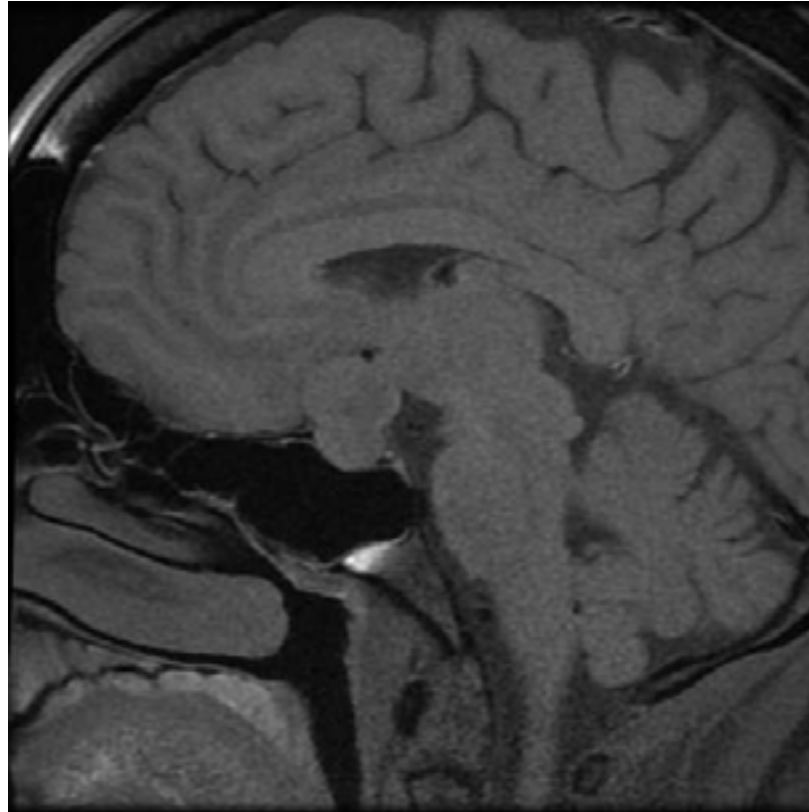


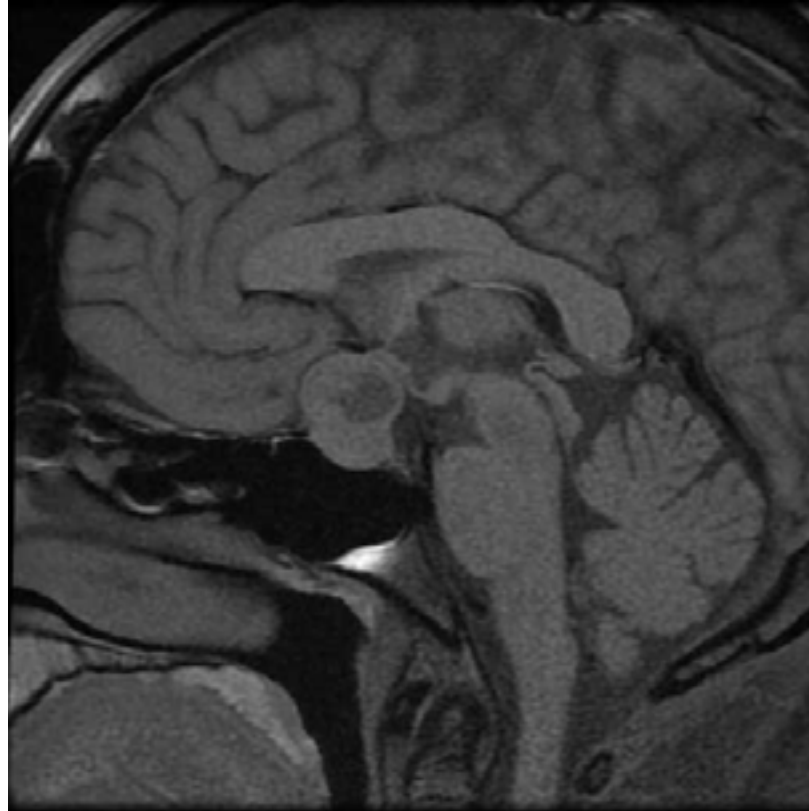
T1 Sequence w/o Contrast

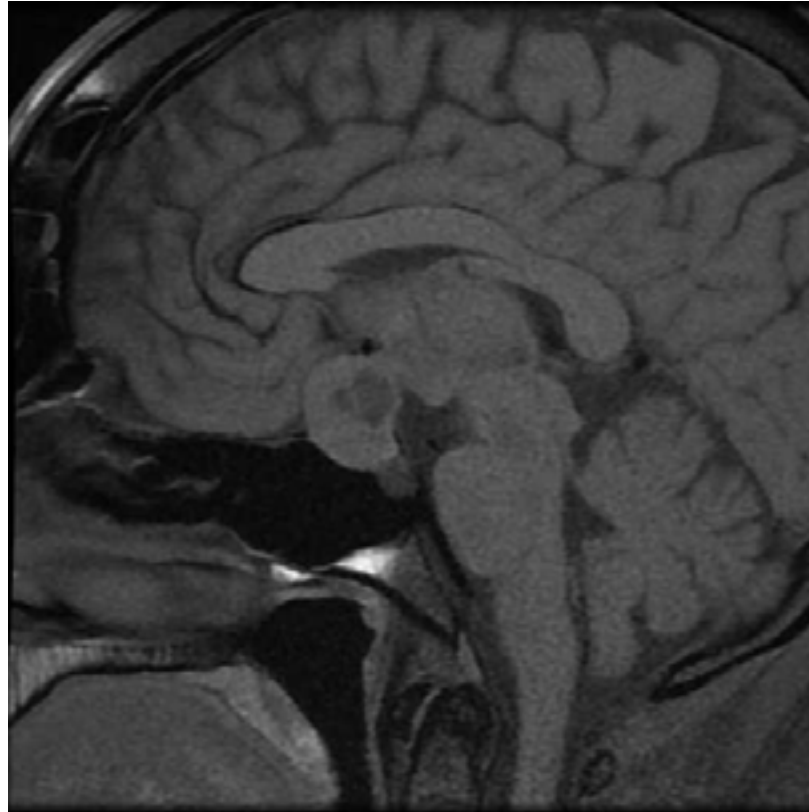
Sagittal

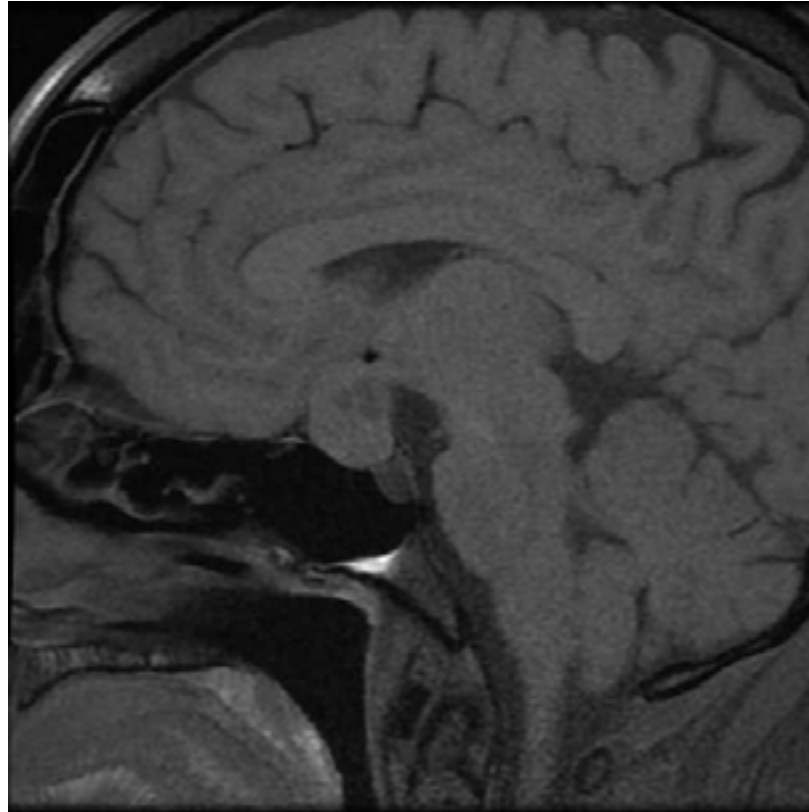




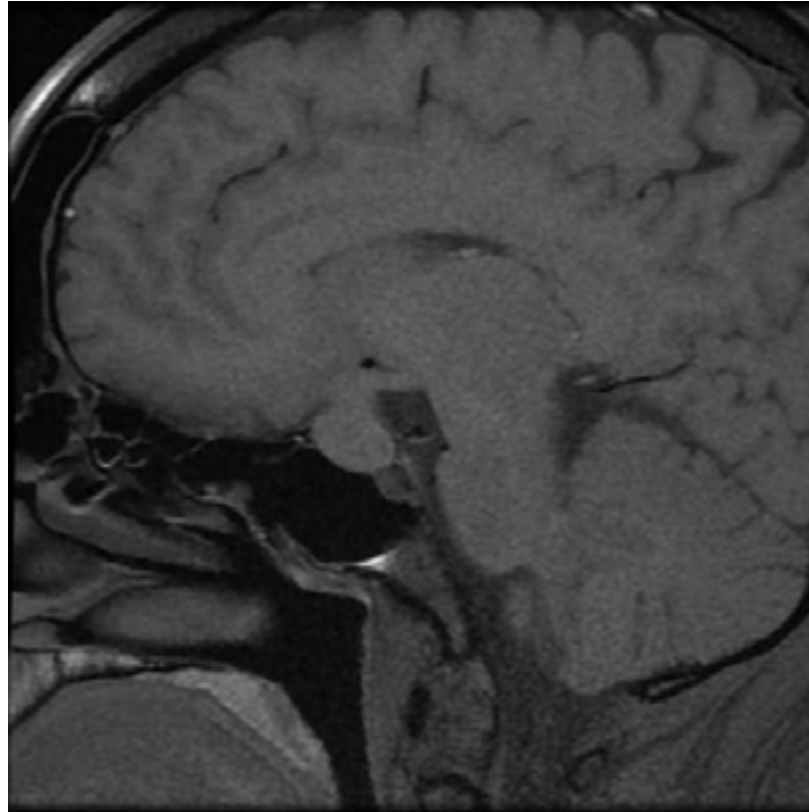


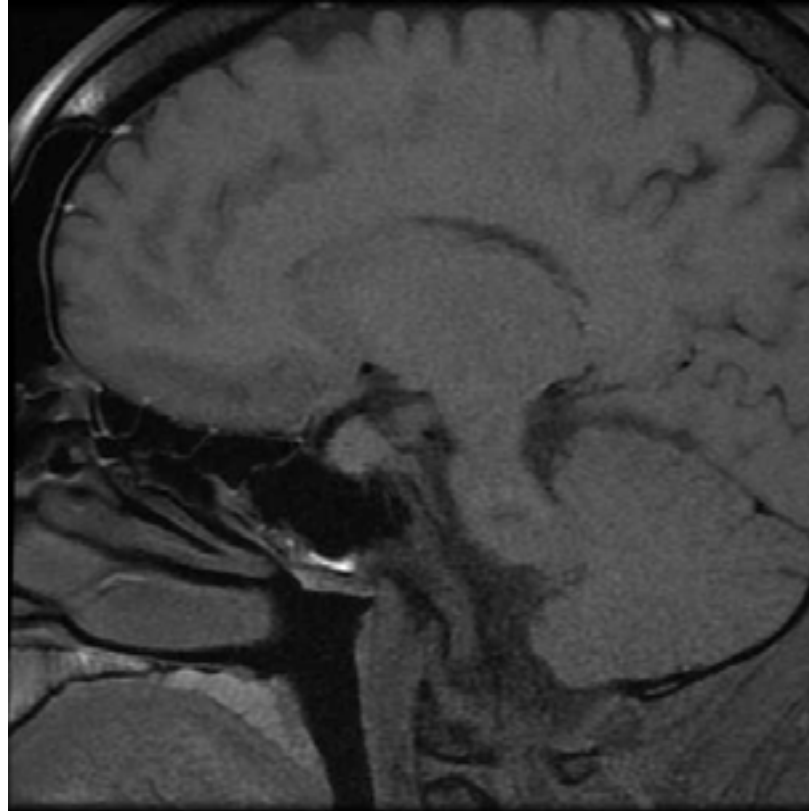


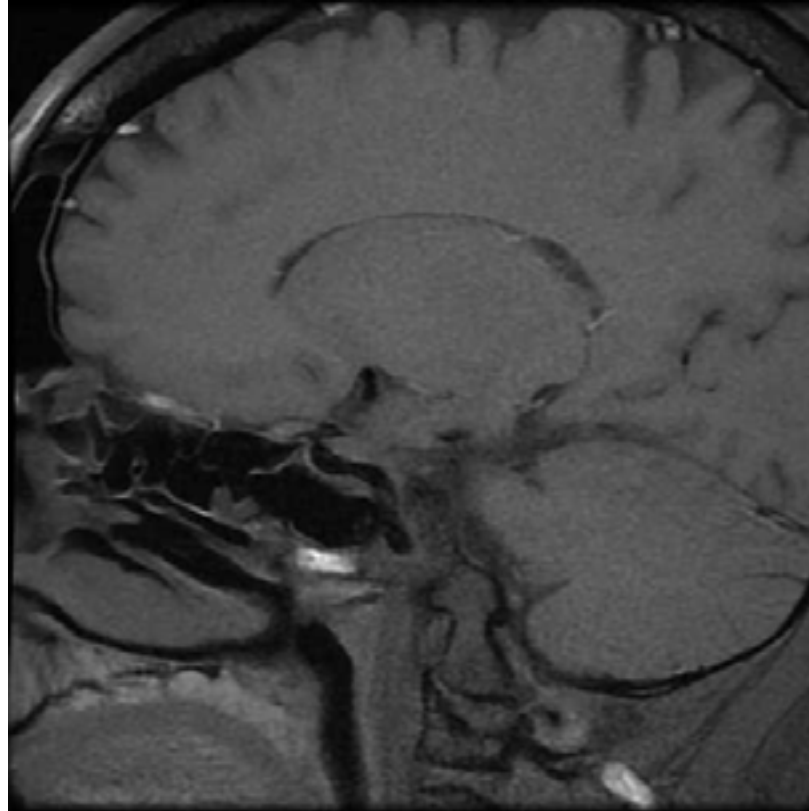








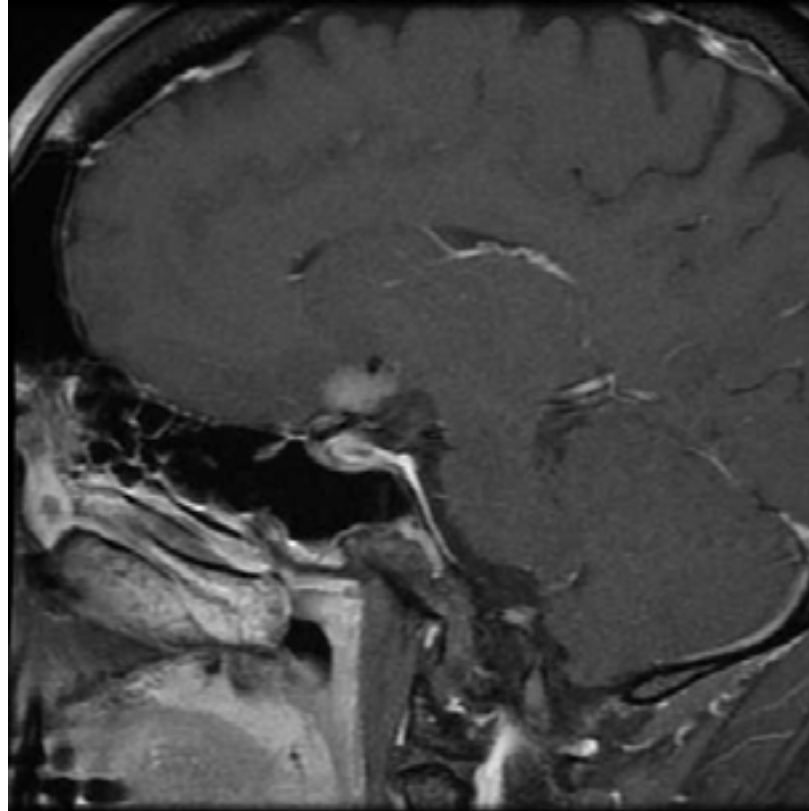


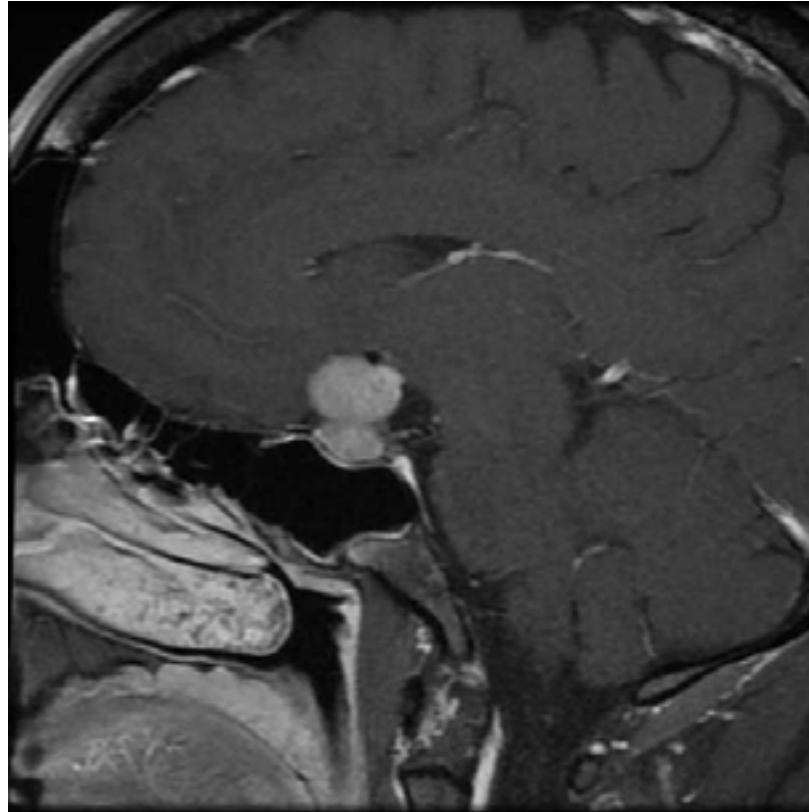


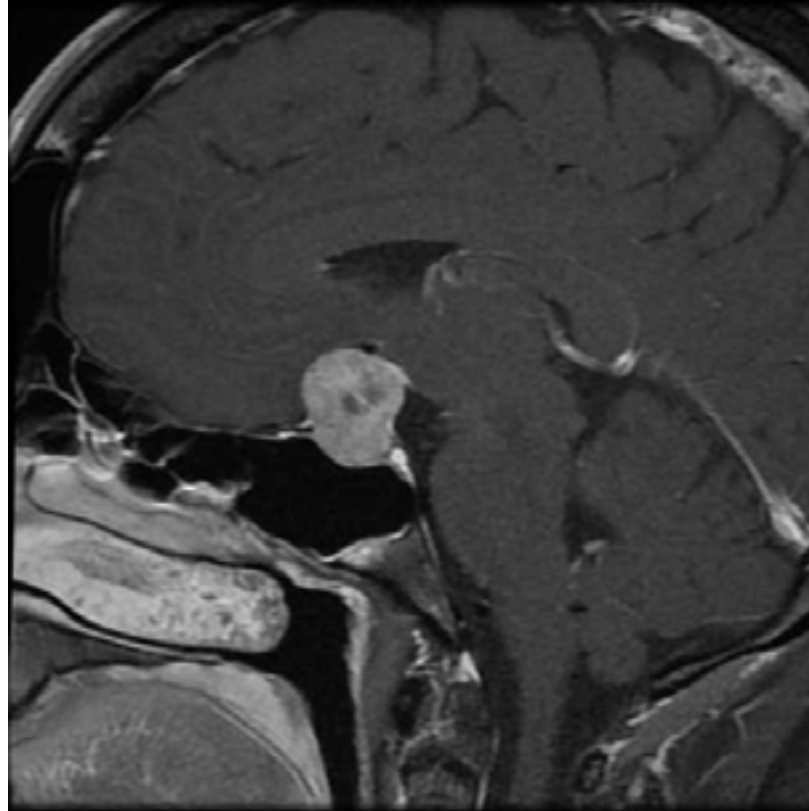


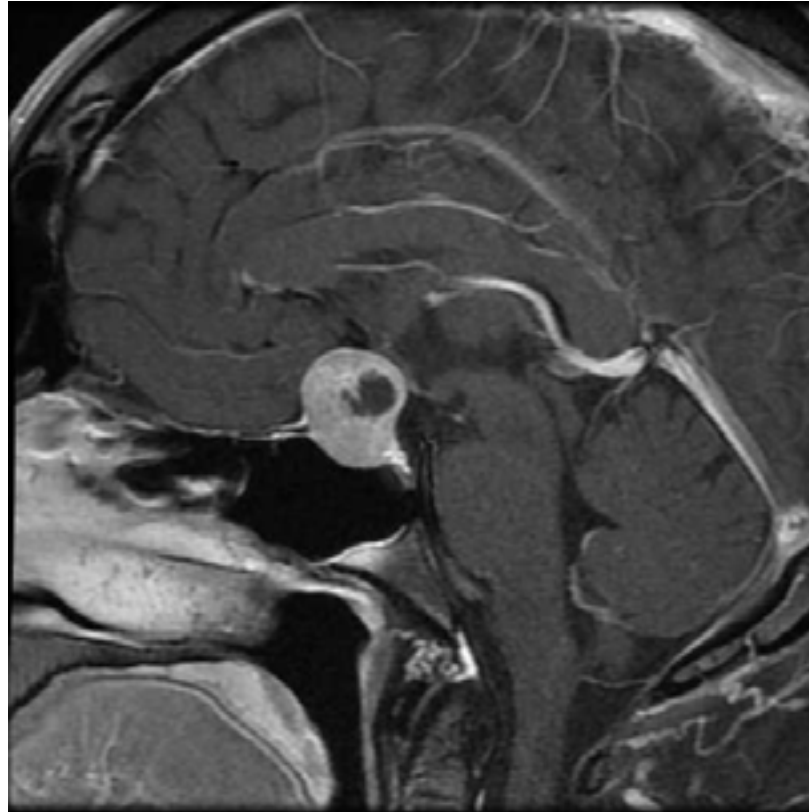
T1 Sequence w/ Contrast

Sagittal

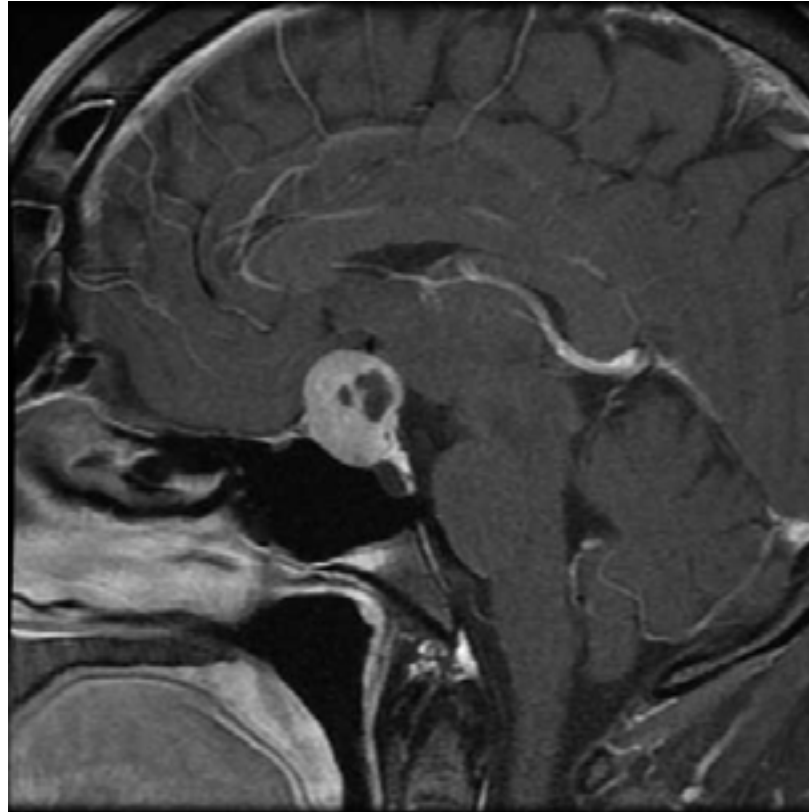


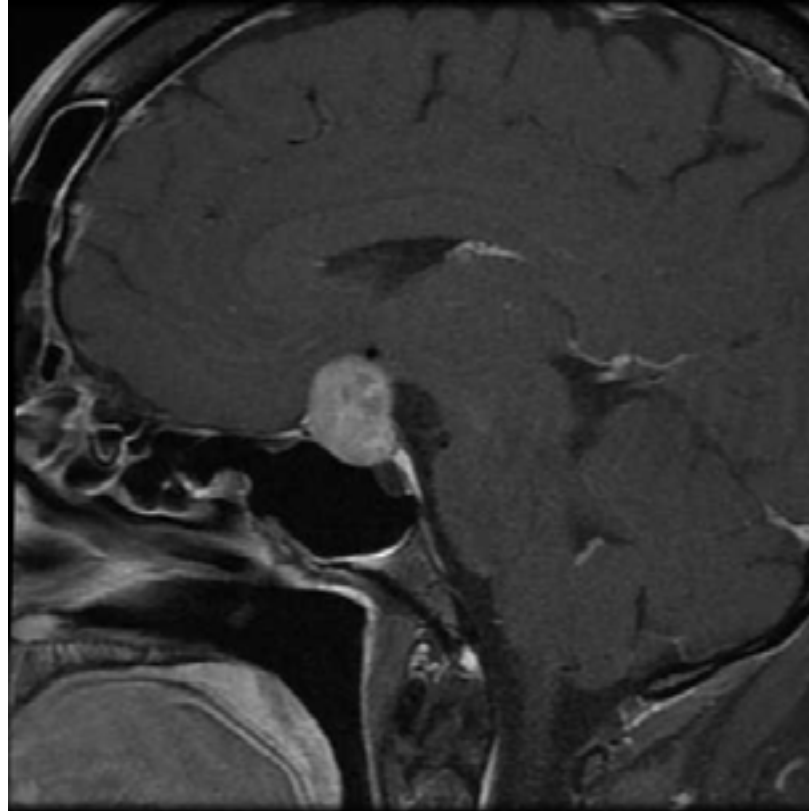


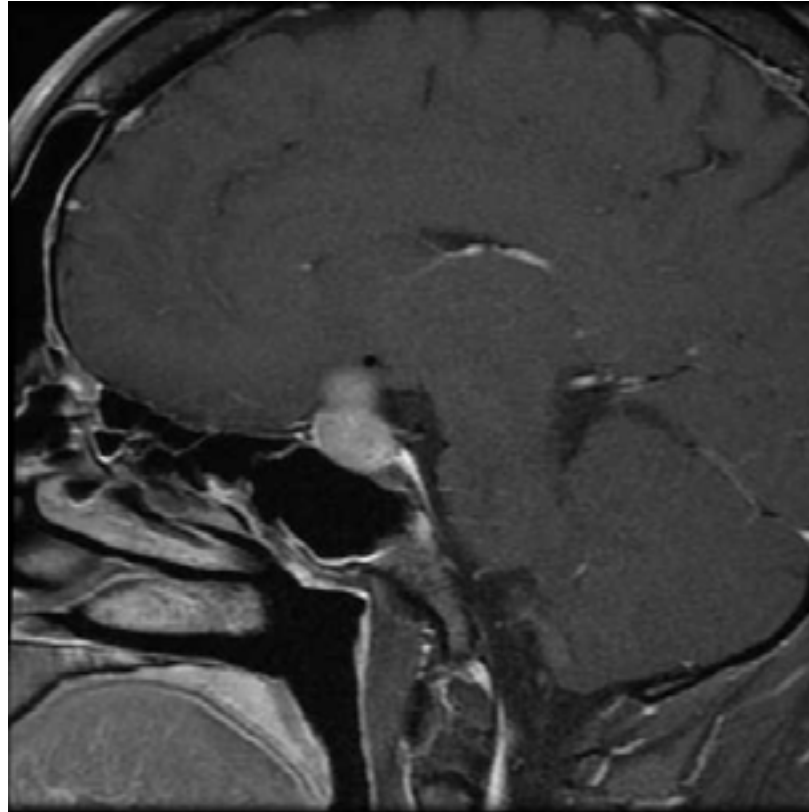


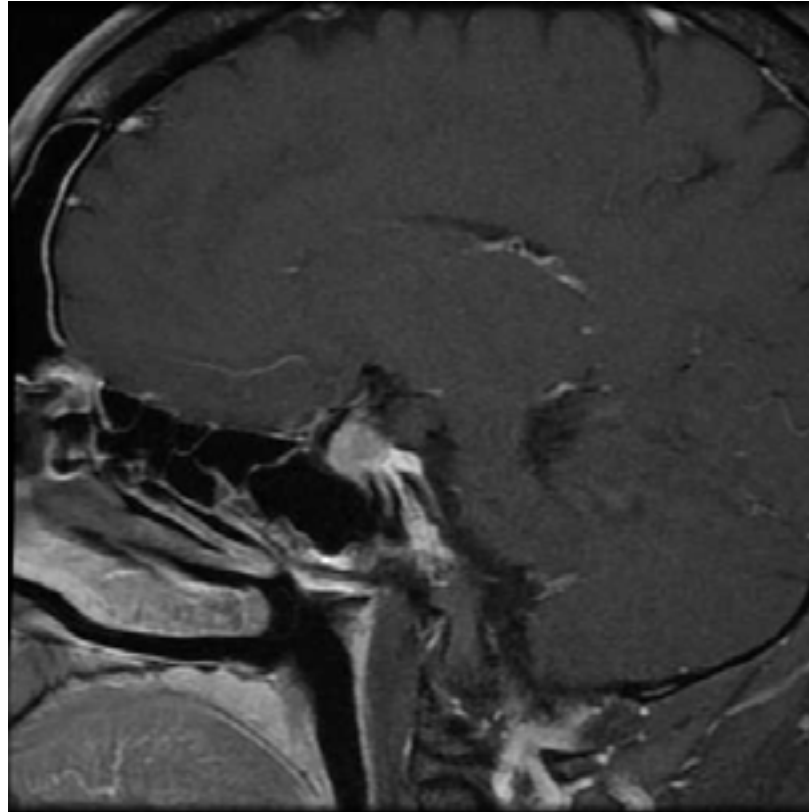


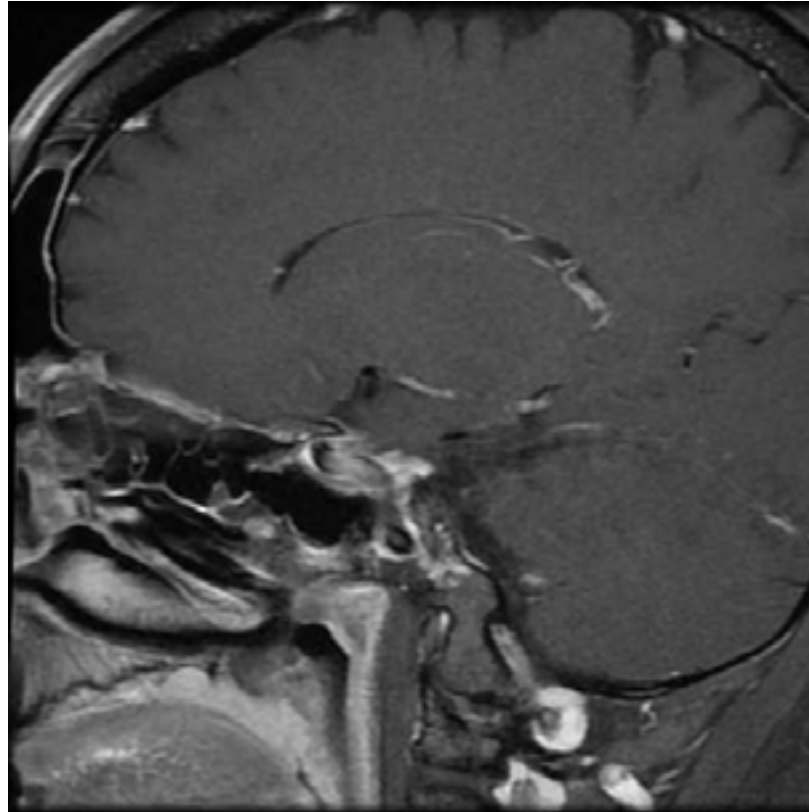




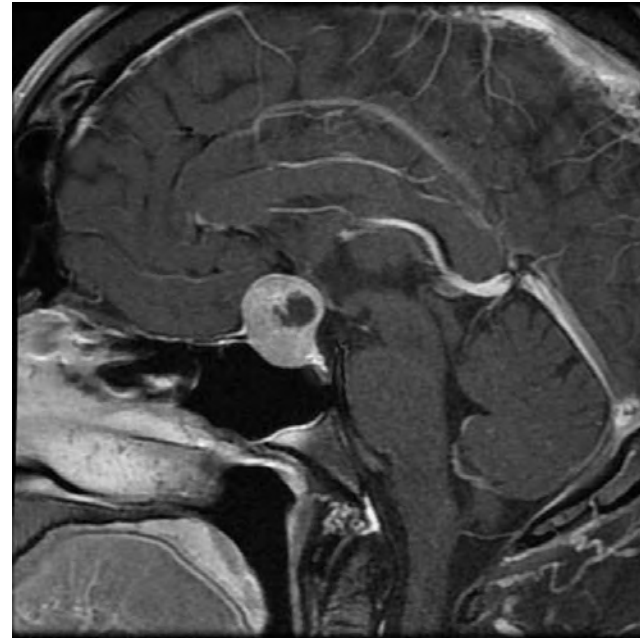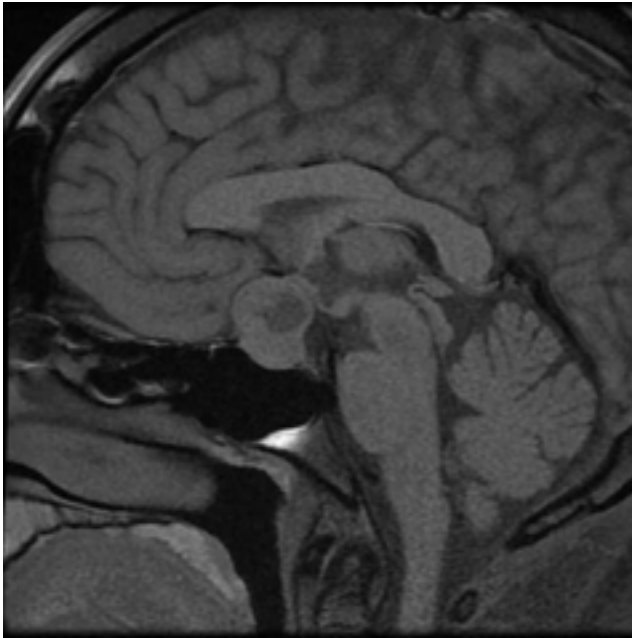








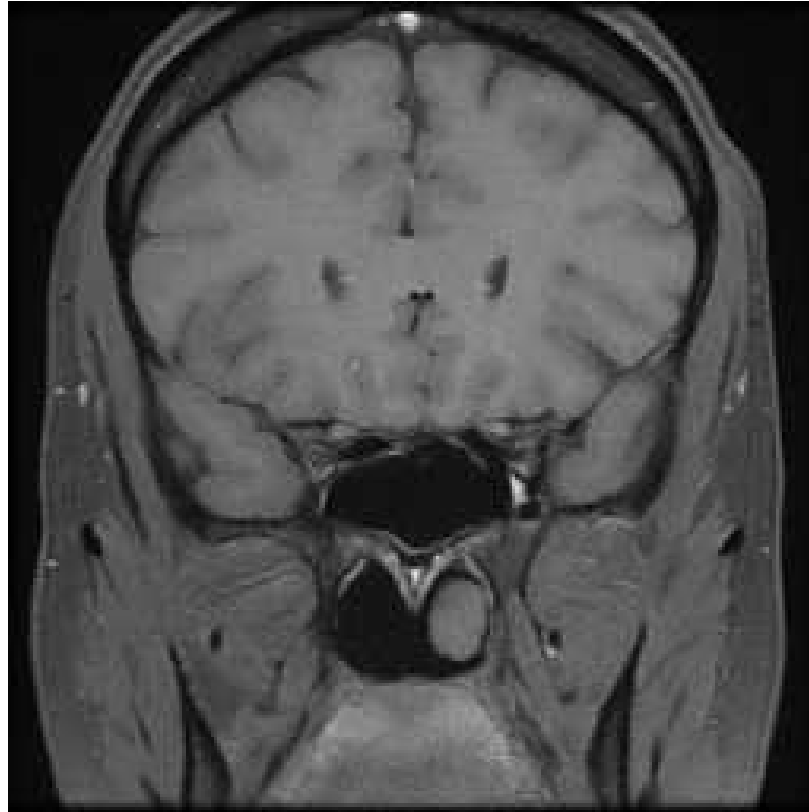
# Contrast vs. No Contrast



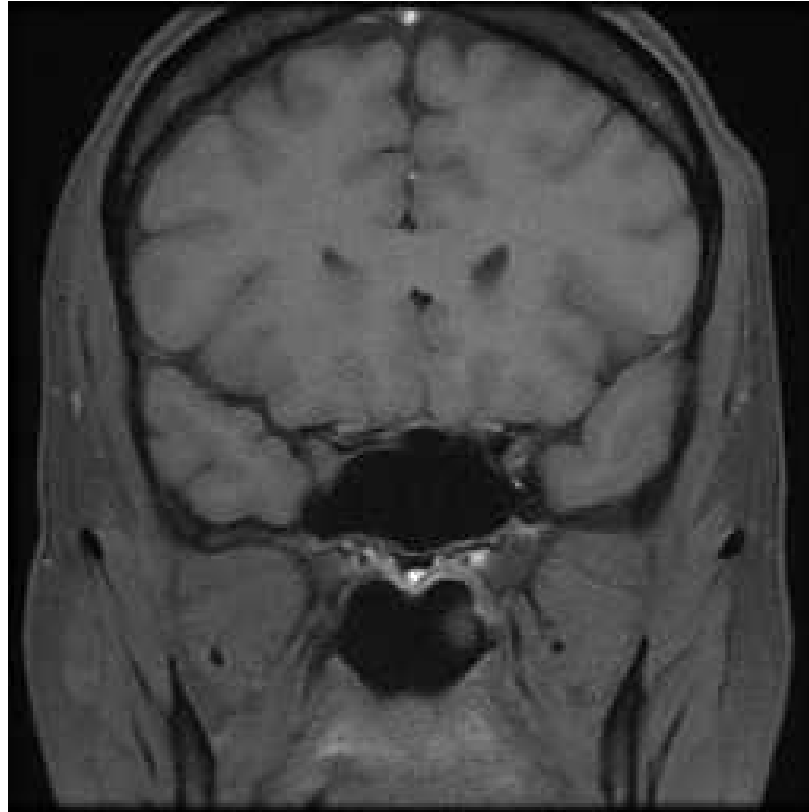


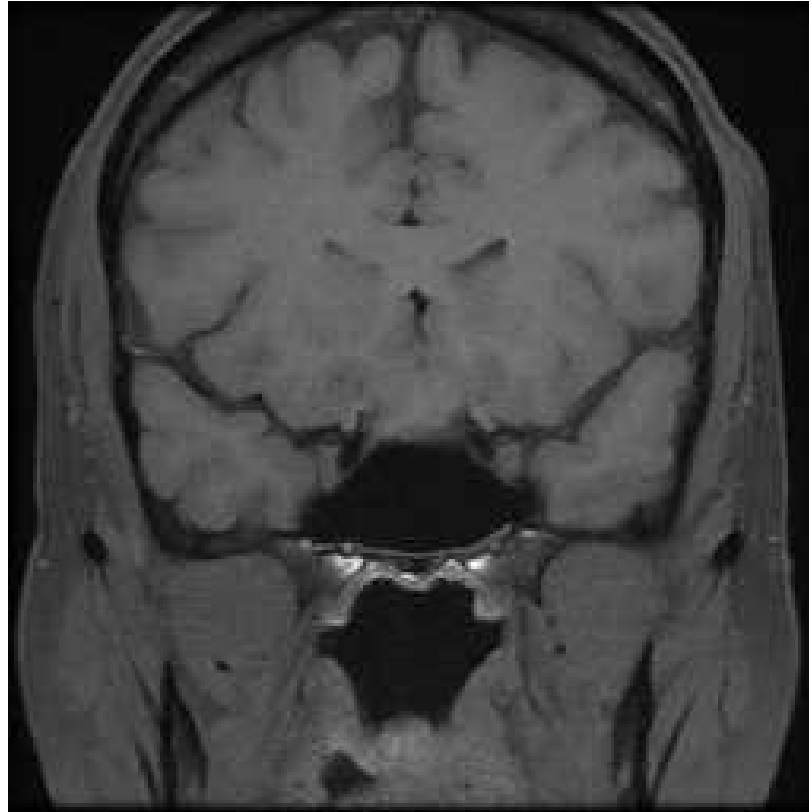
T1 Sequence w/o Contrast

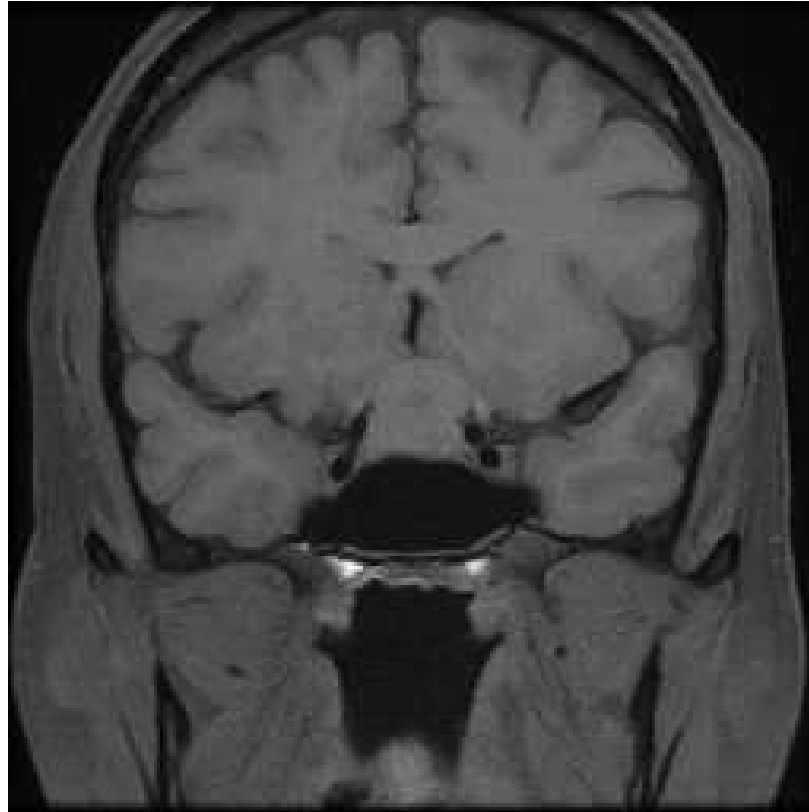
Coronal

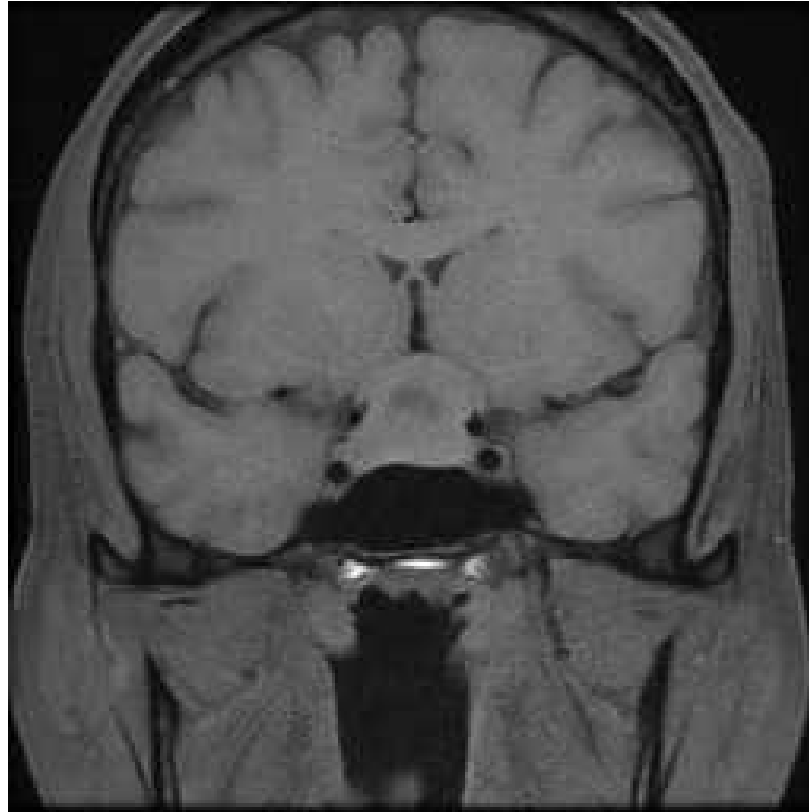


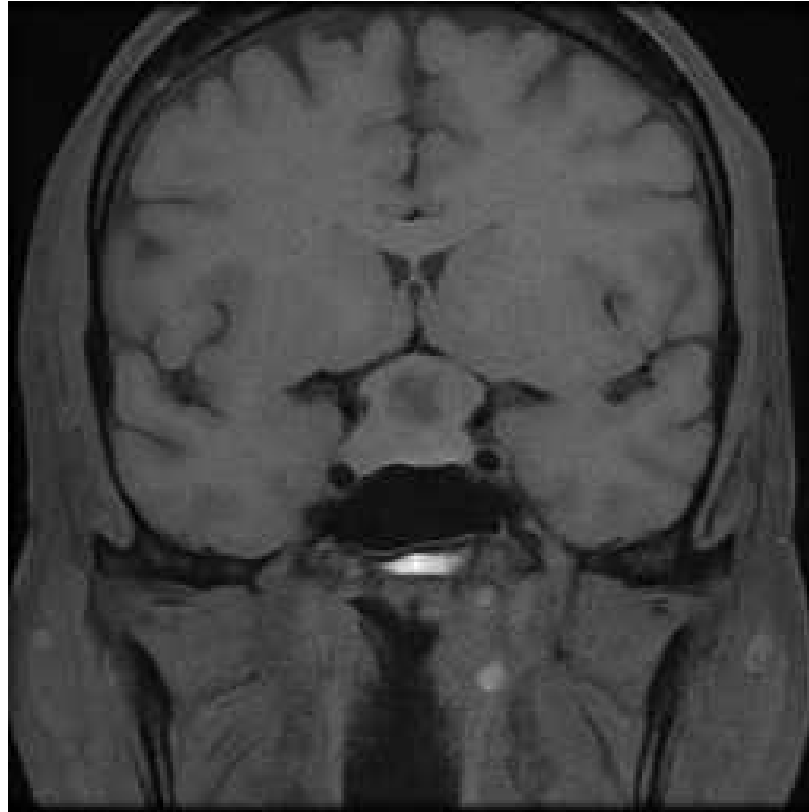


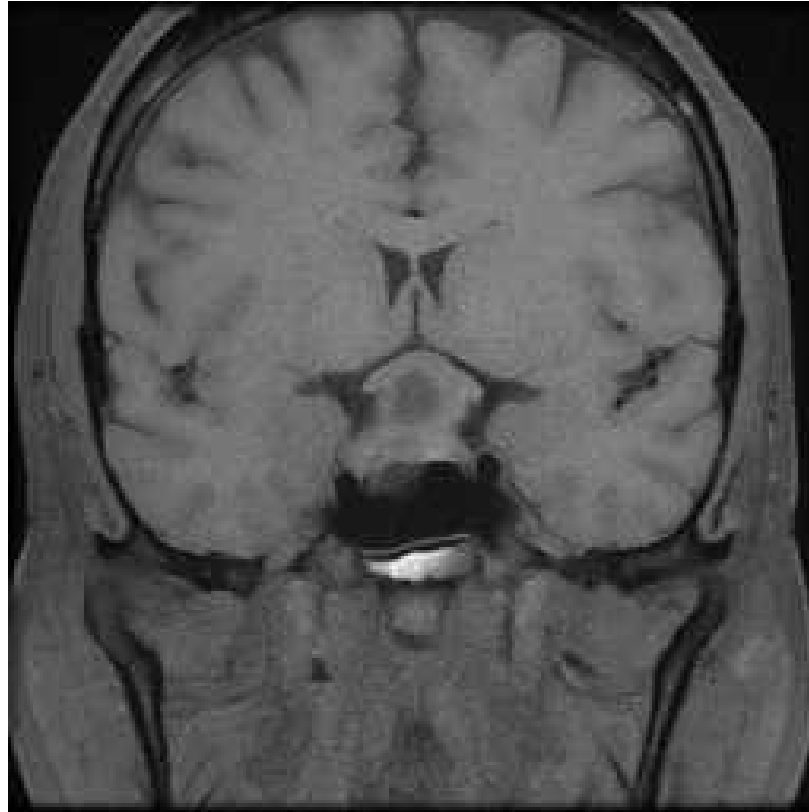


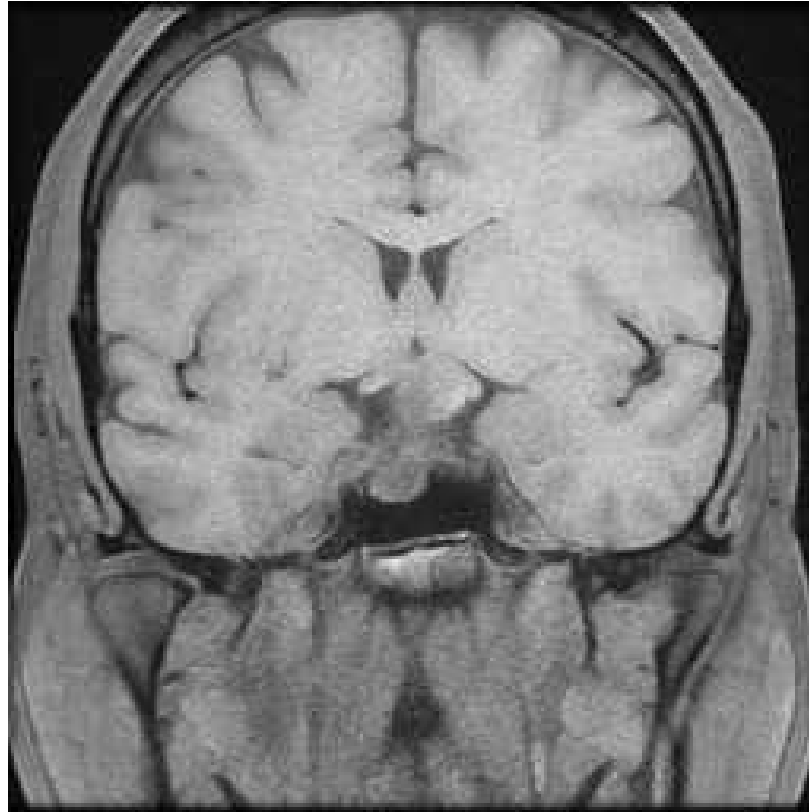


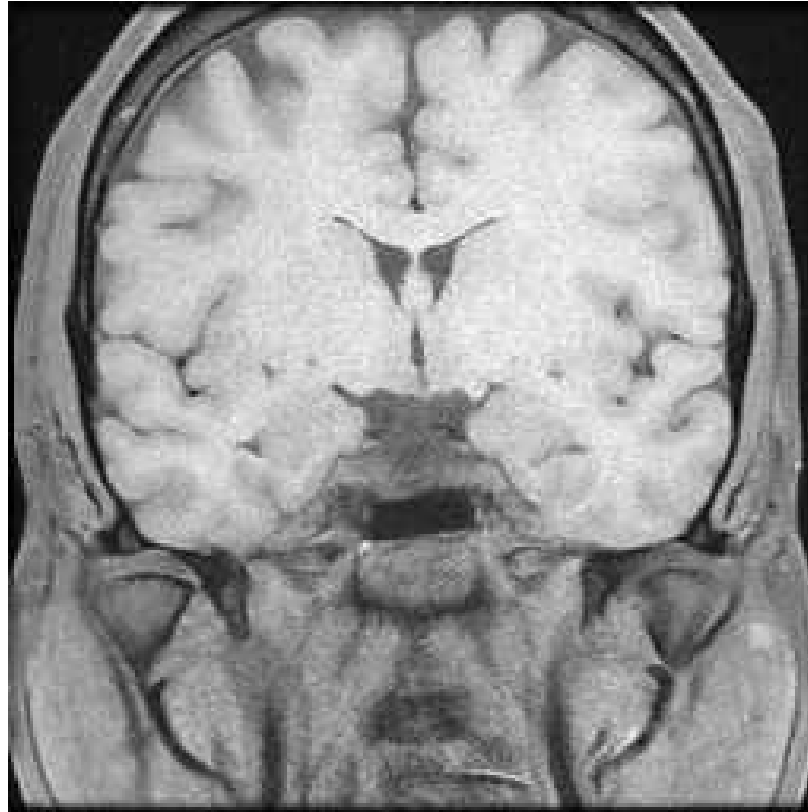




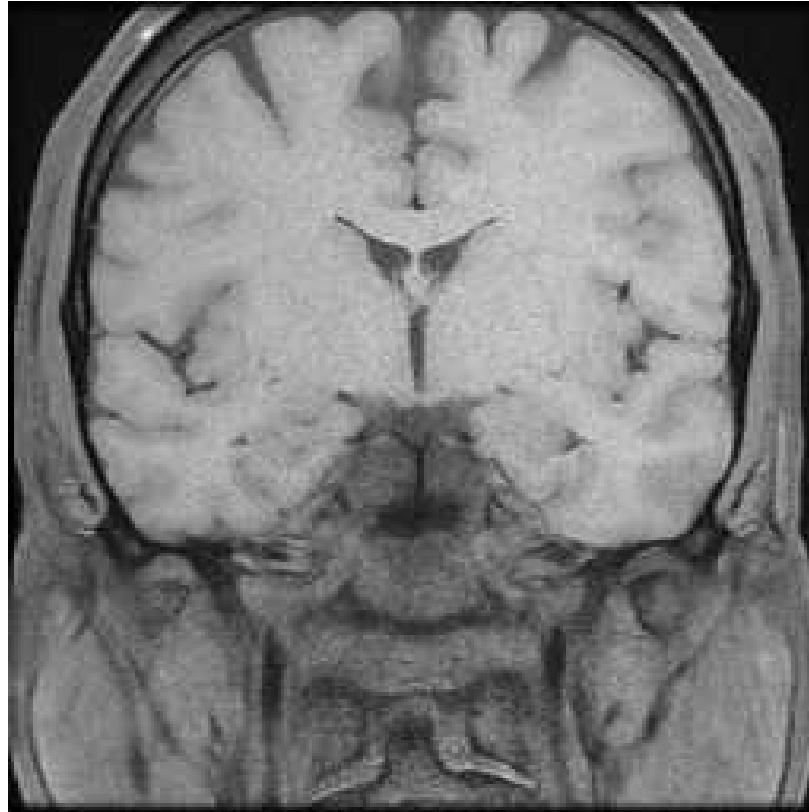


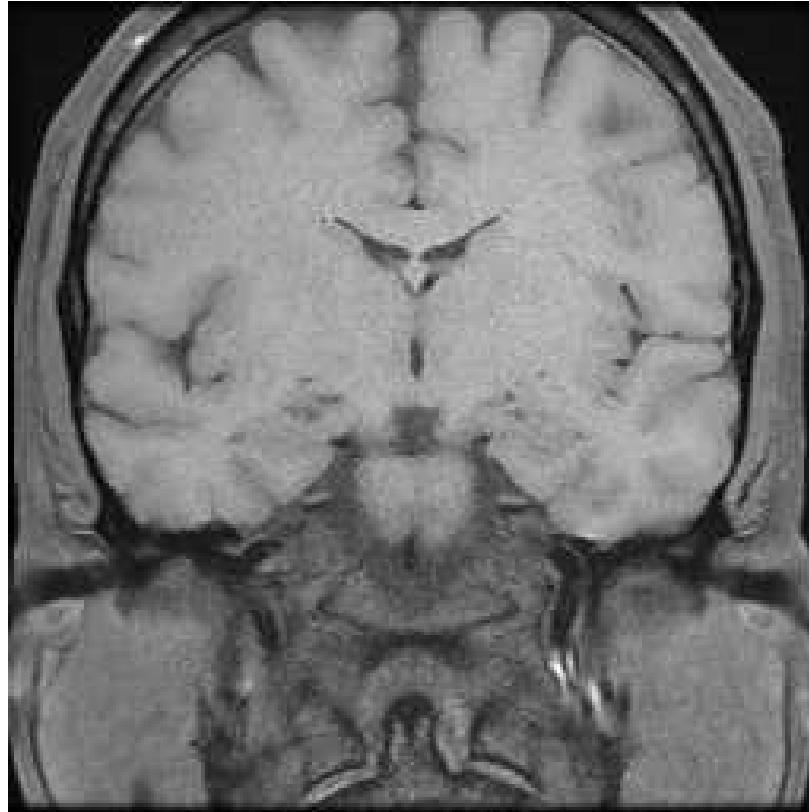


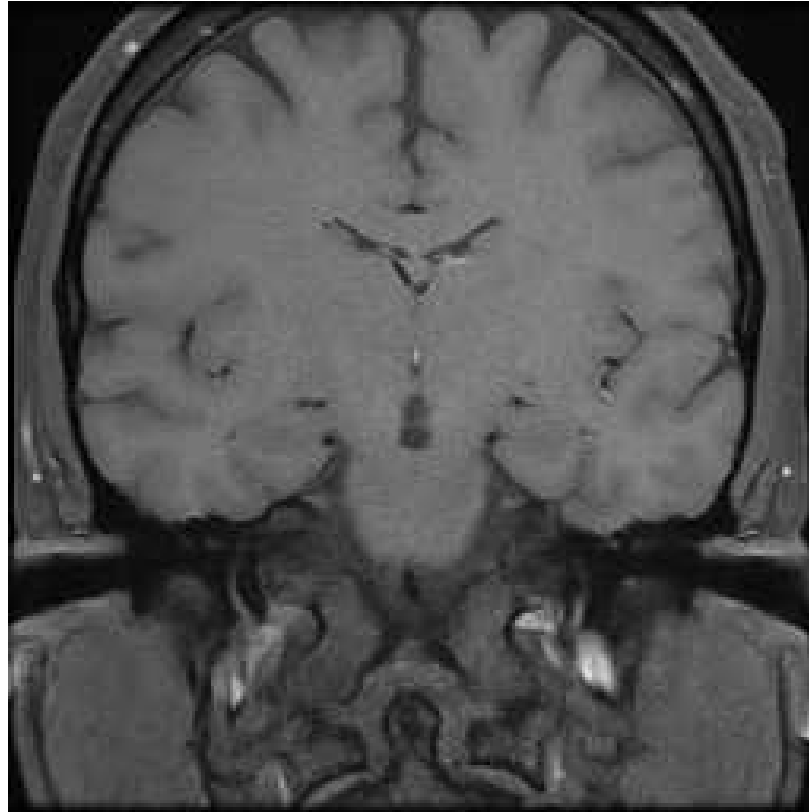








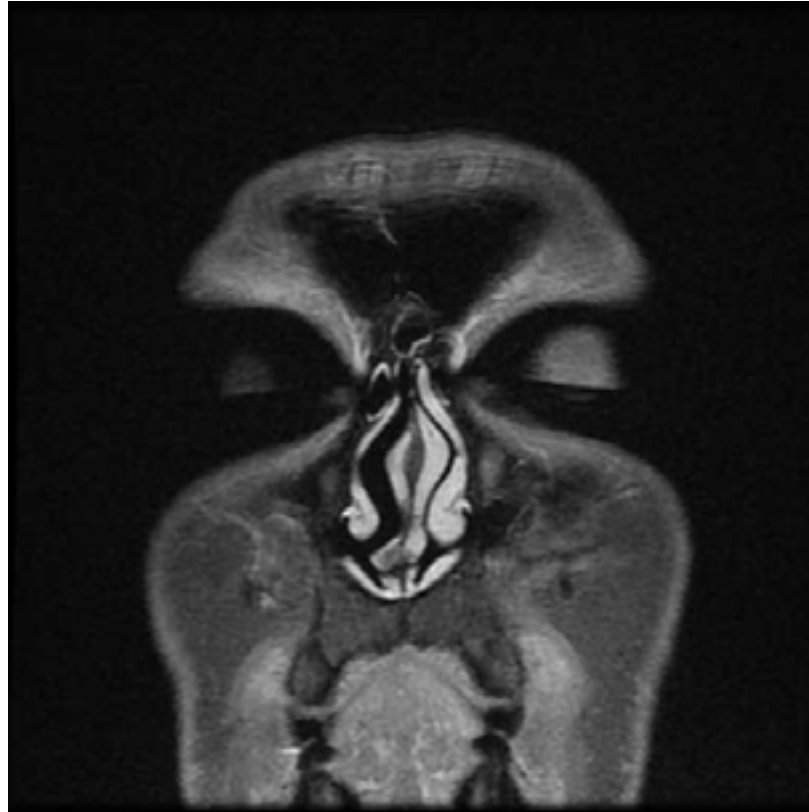


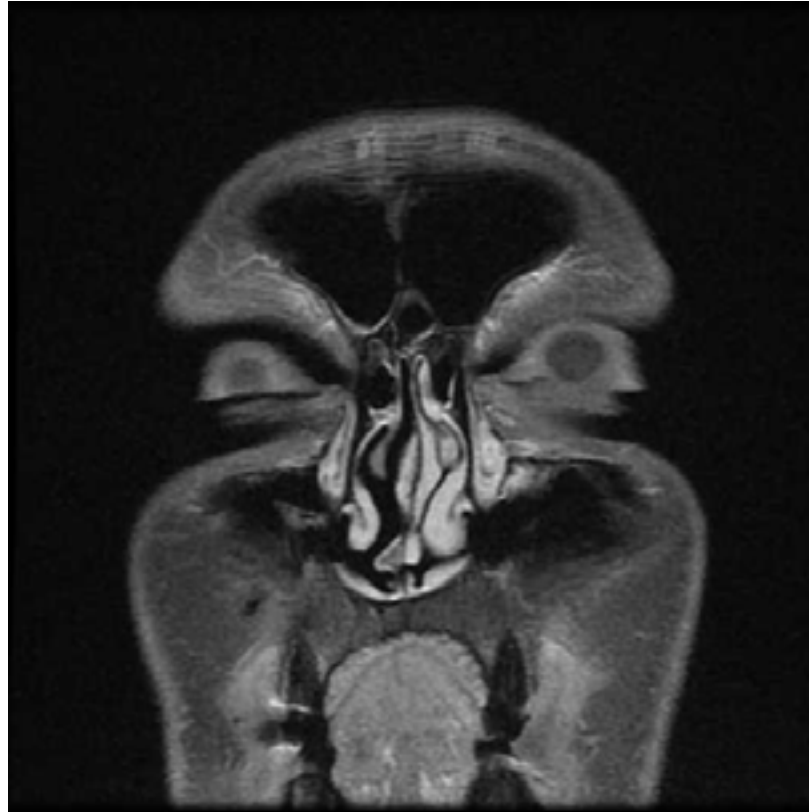


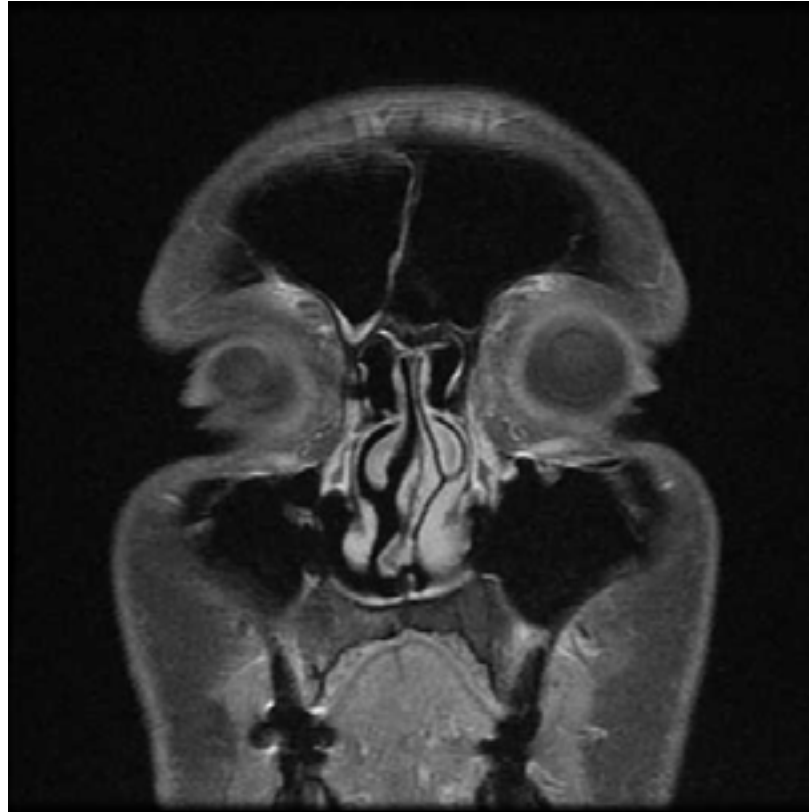


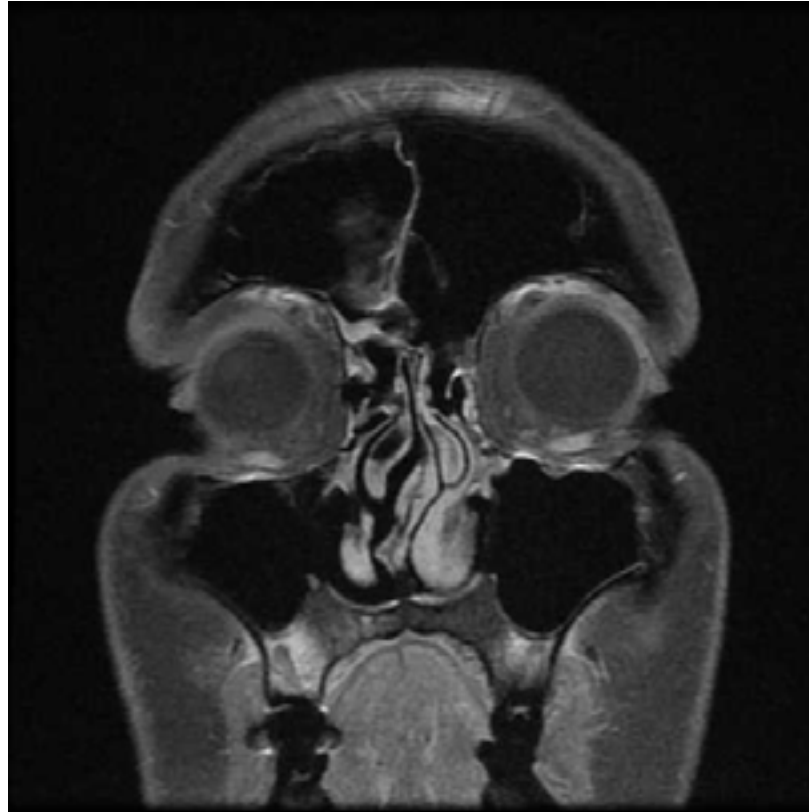T1 Sequence w/ Contrast

Coronal

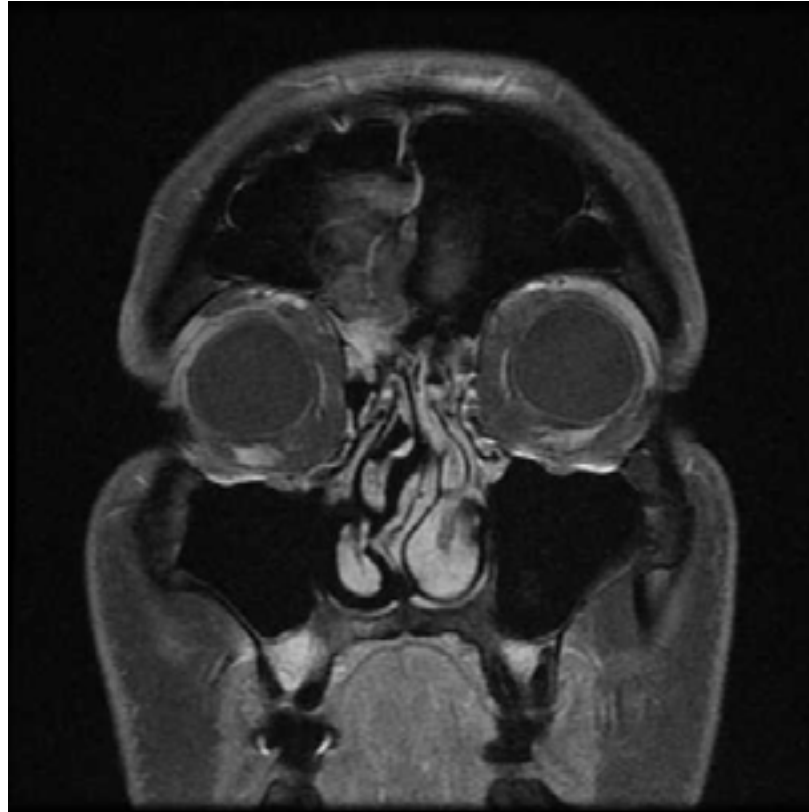


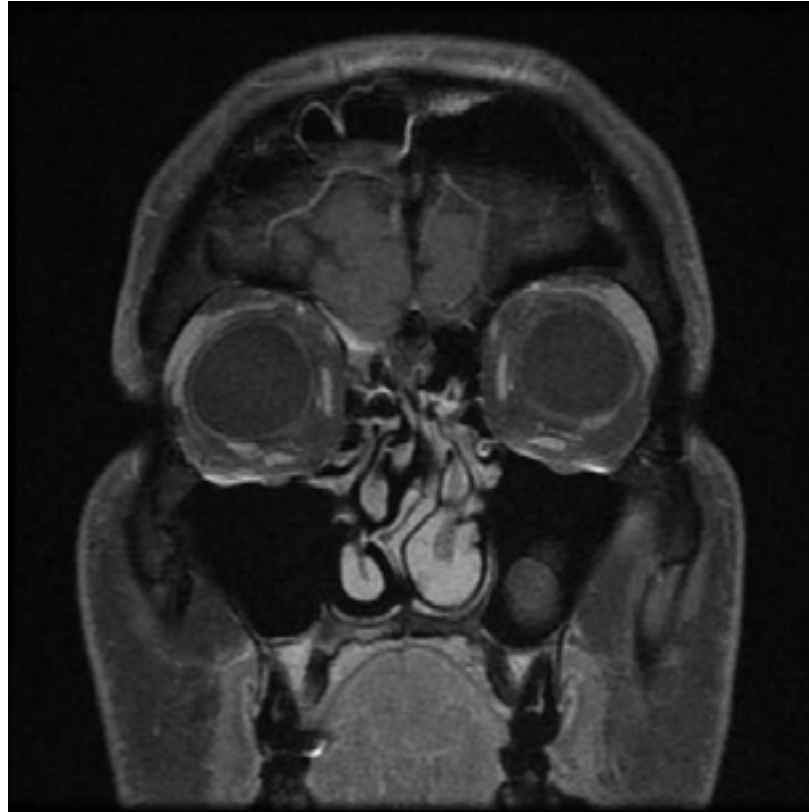


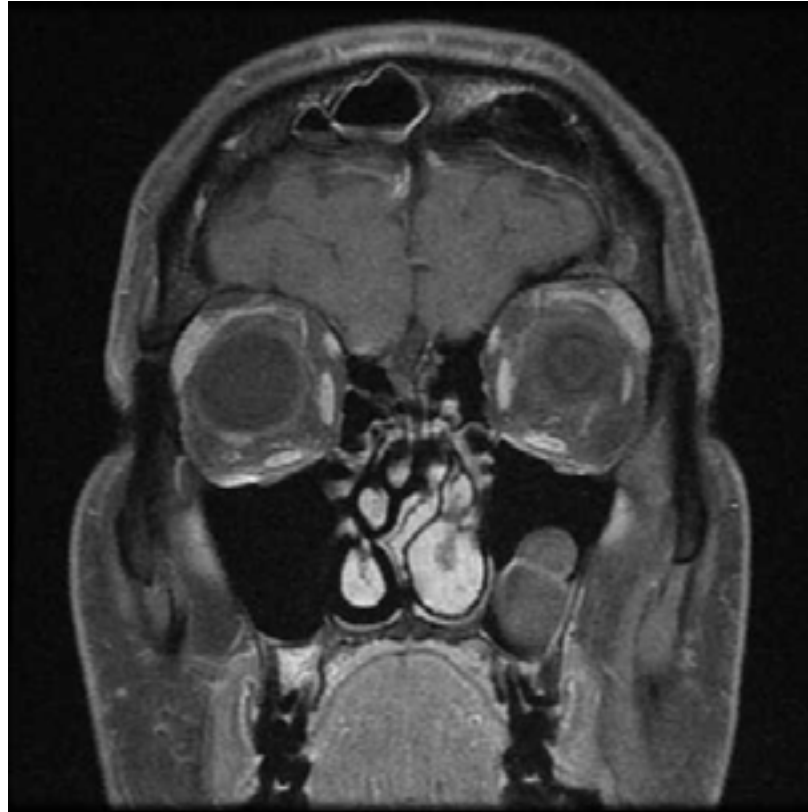


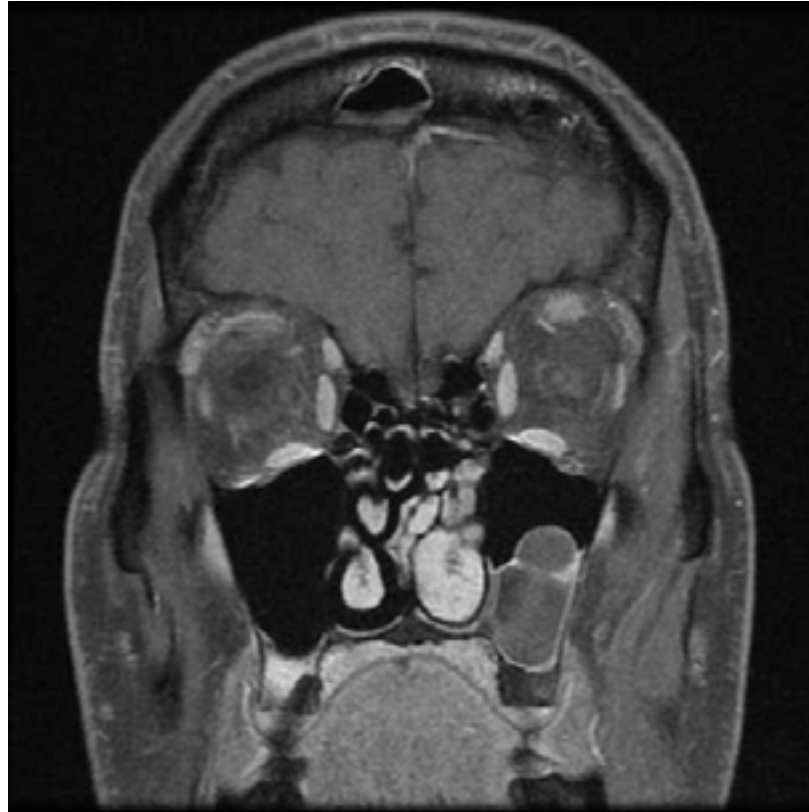


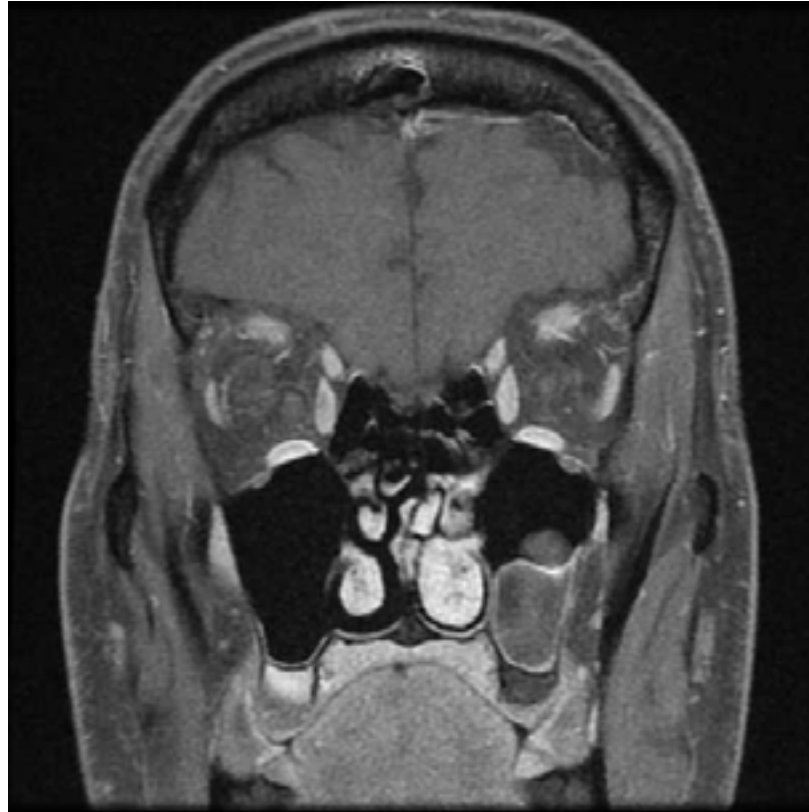
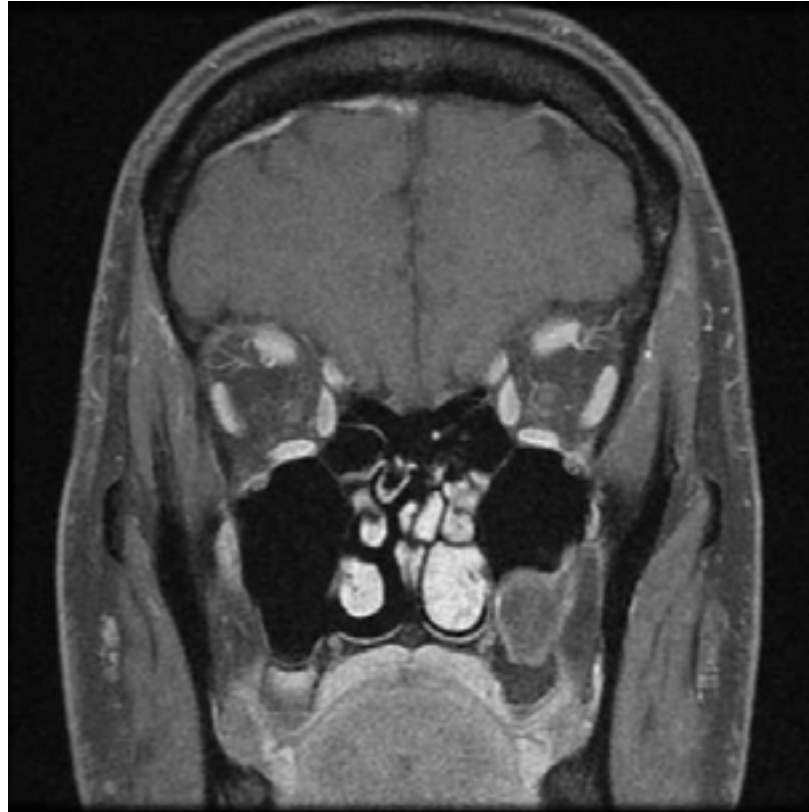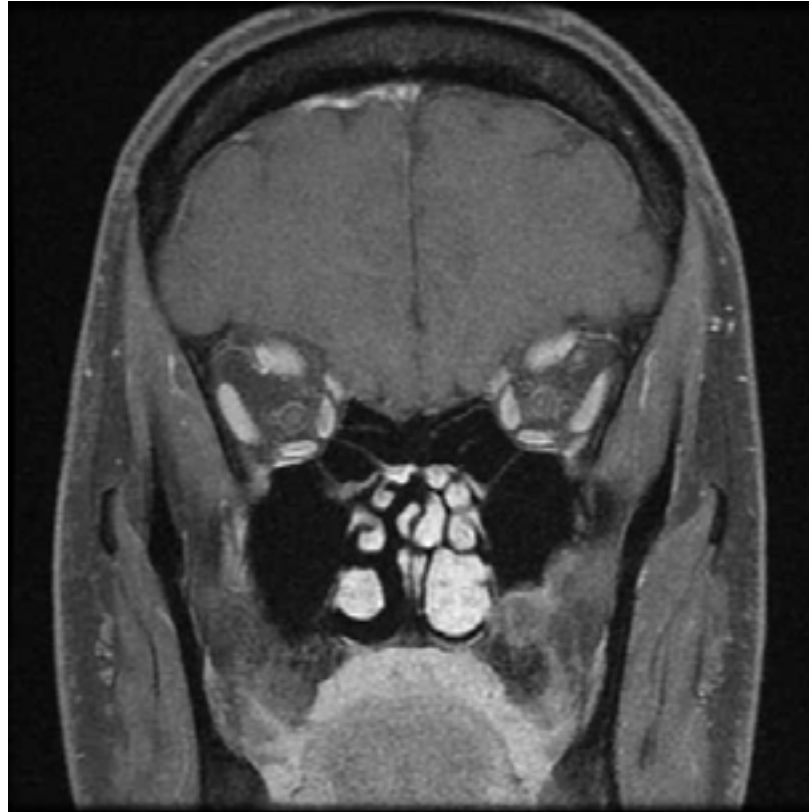


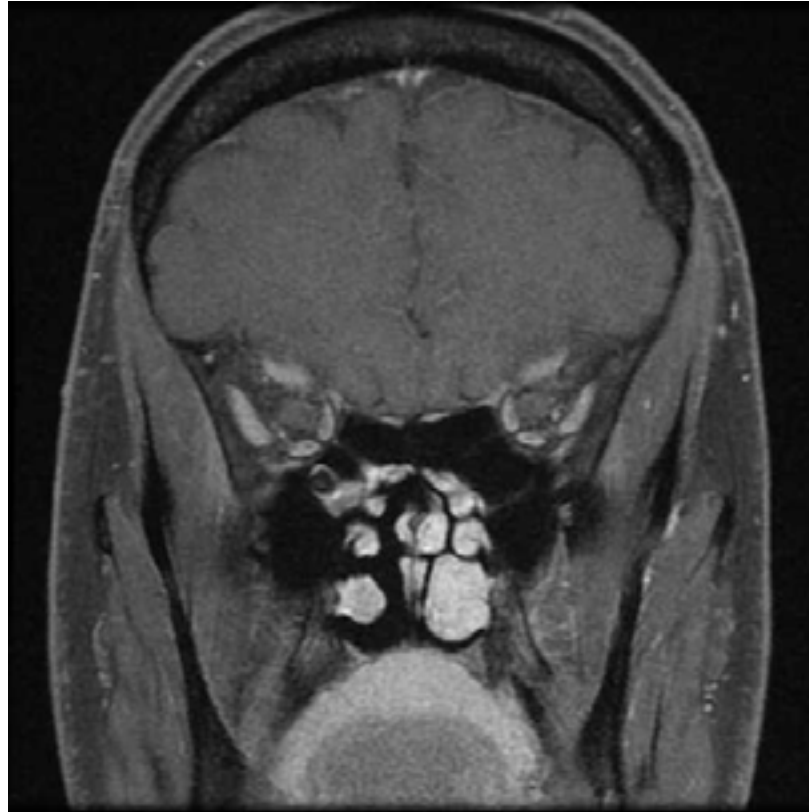




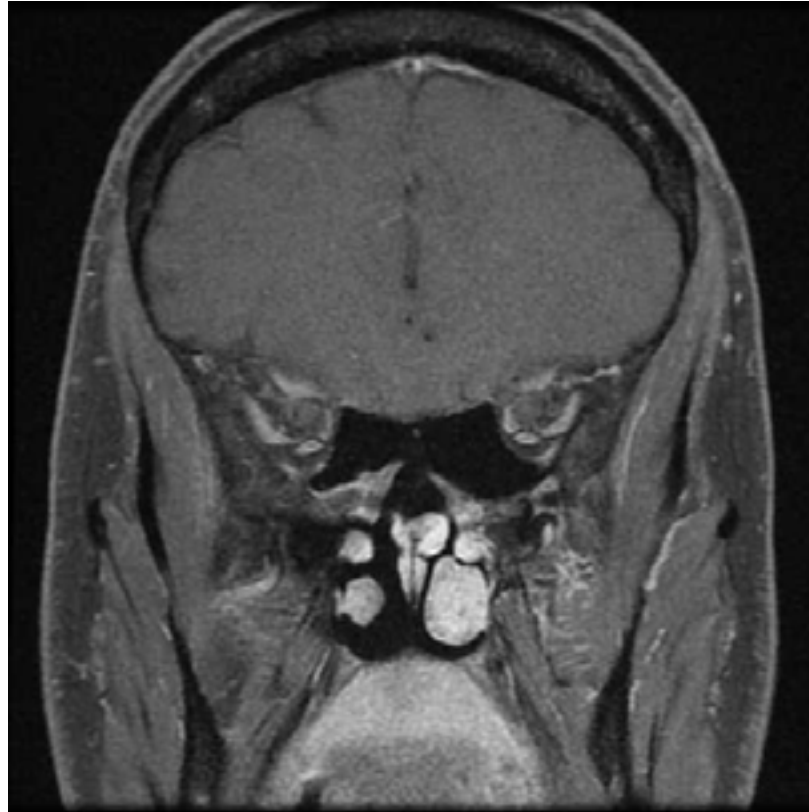


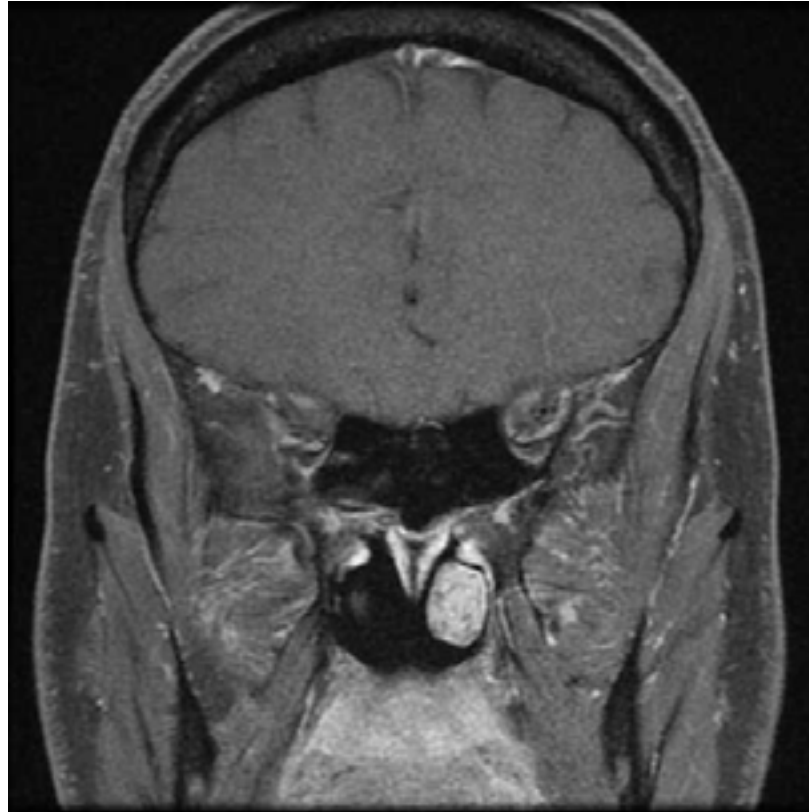


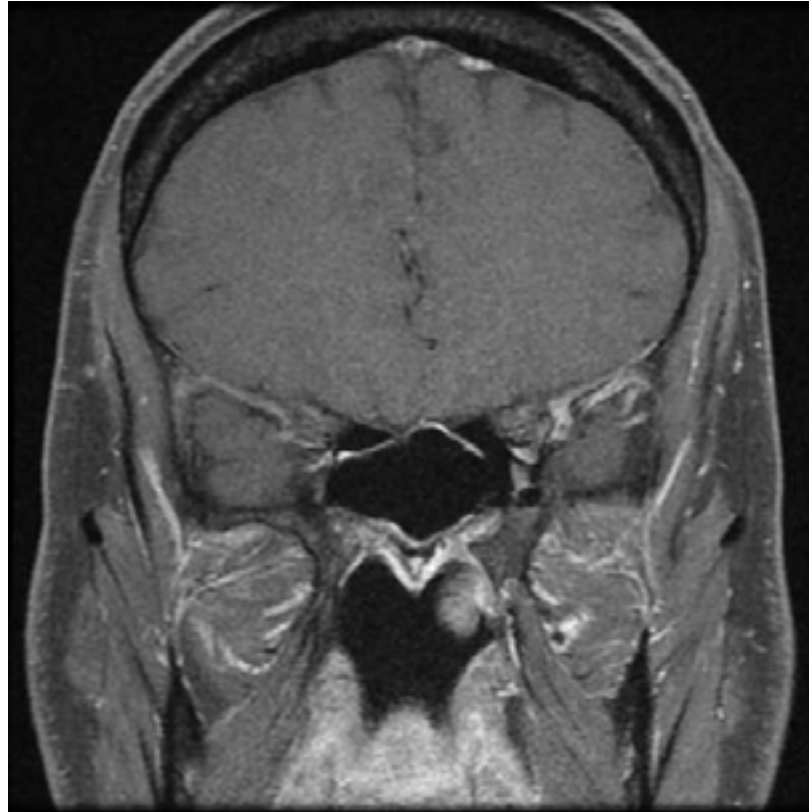


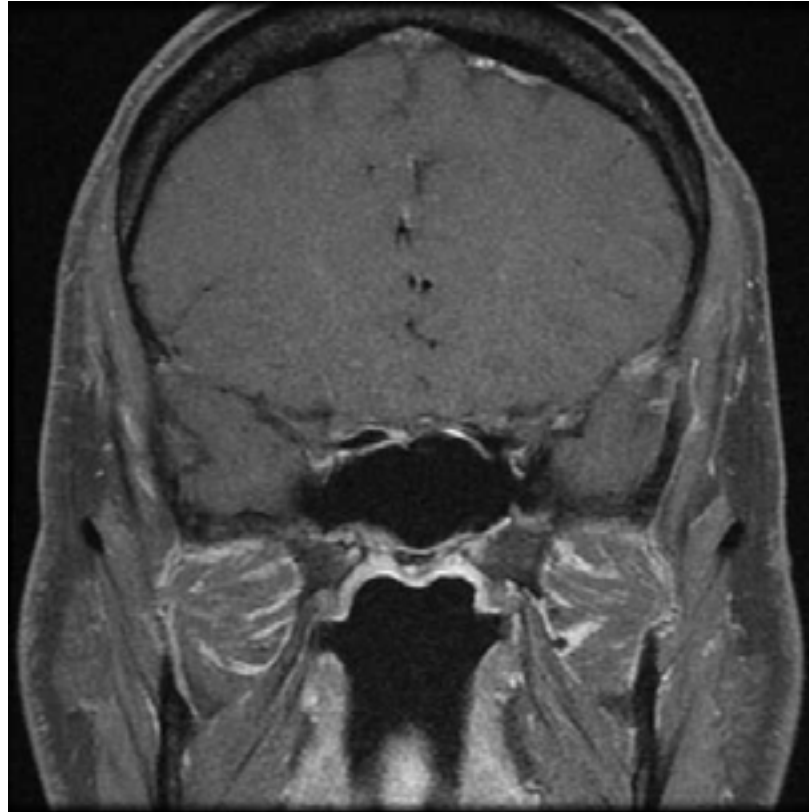


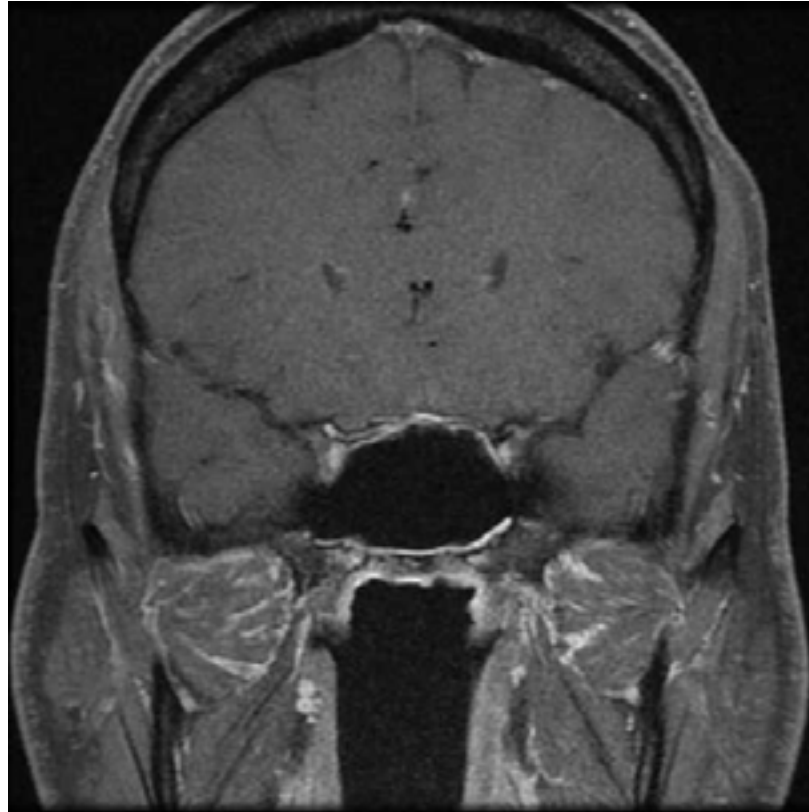


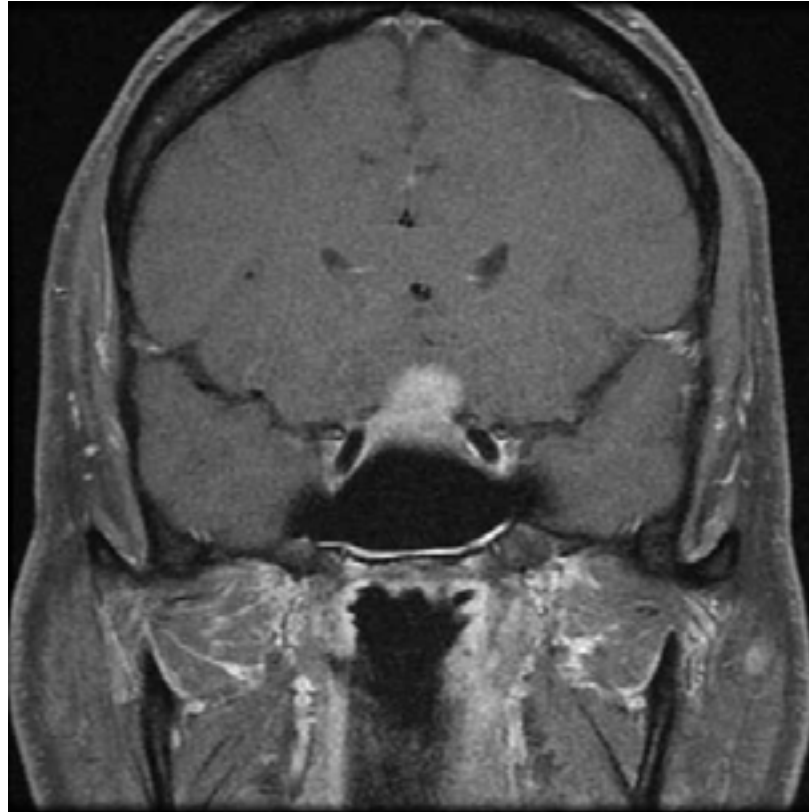


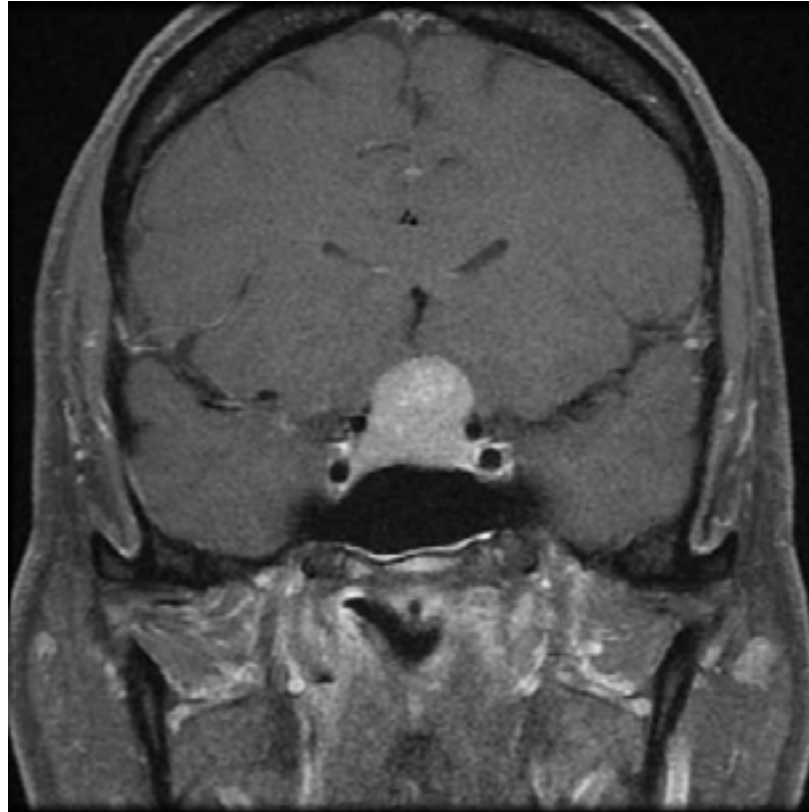


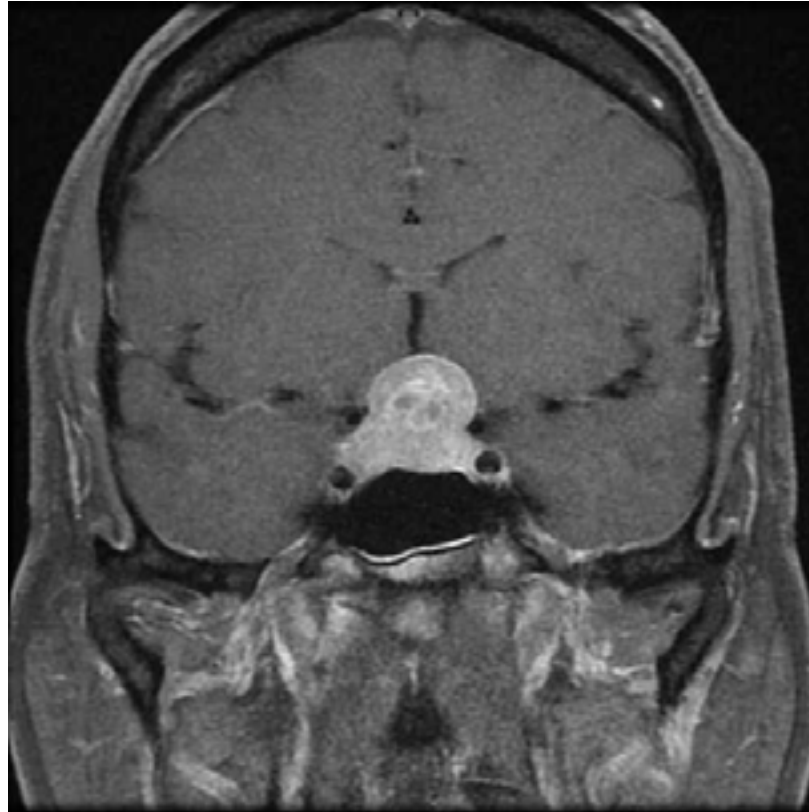




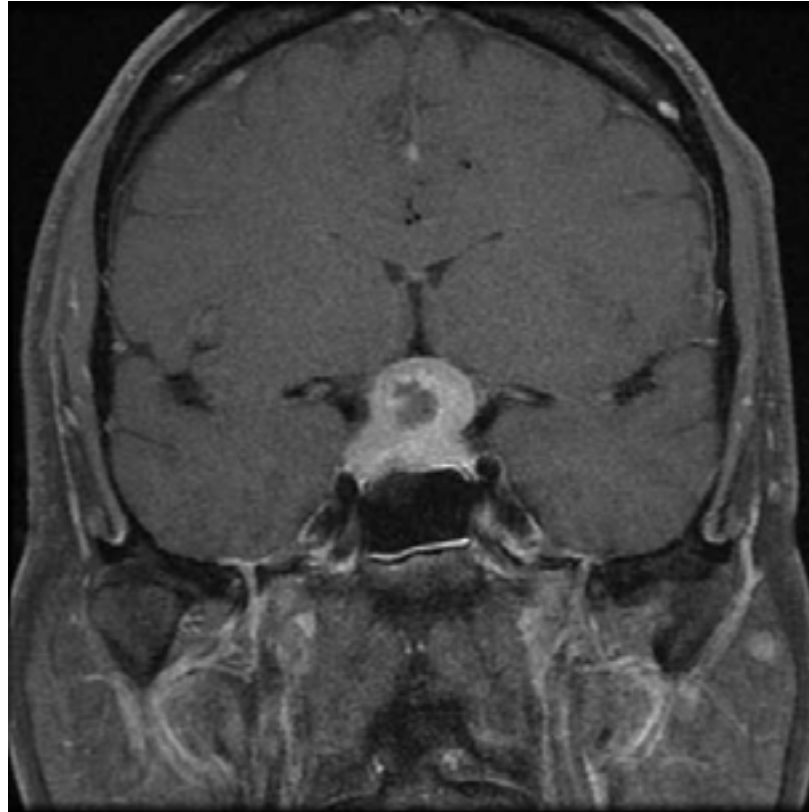


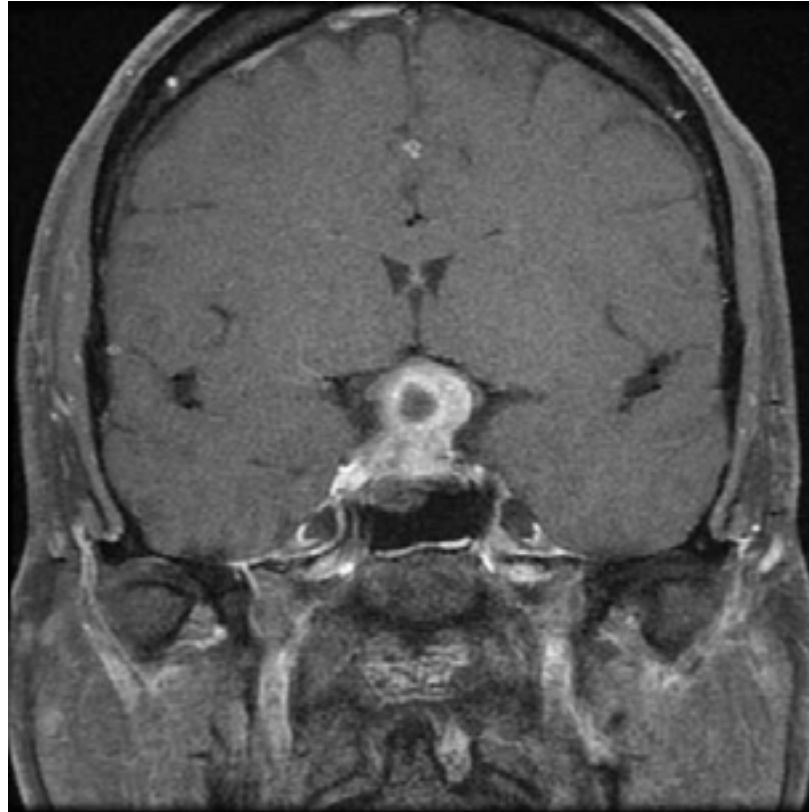


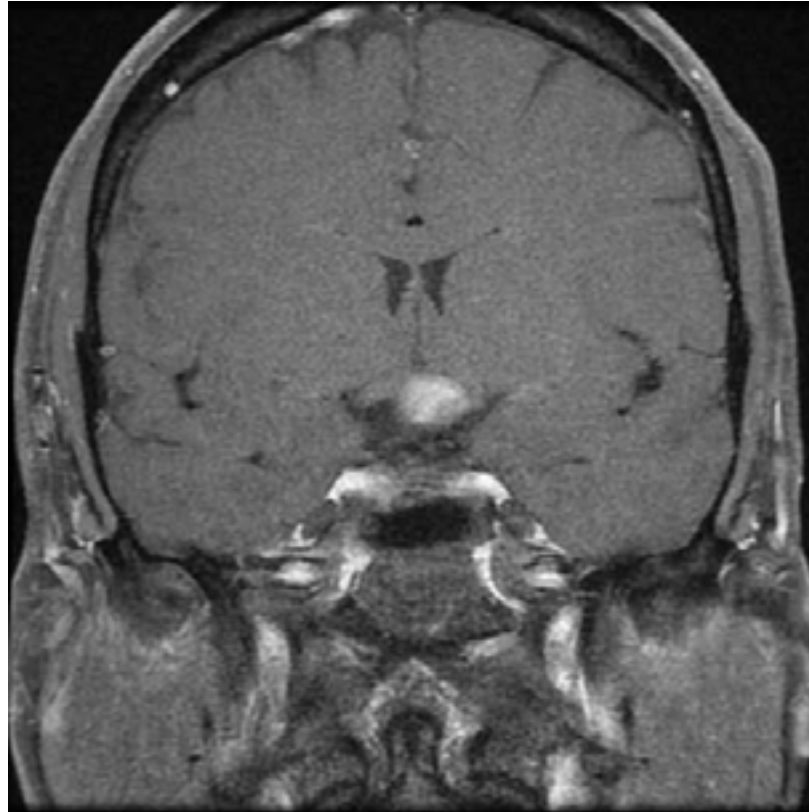


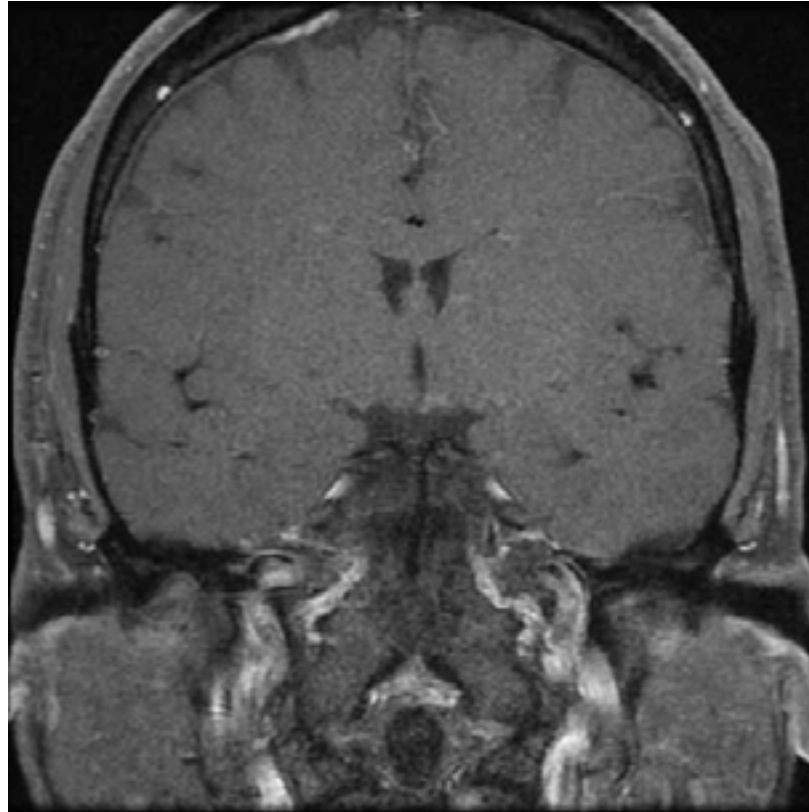


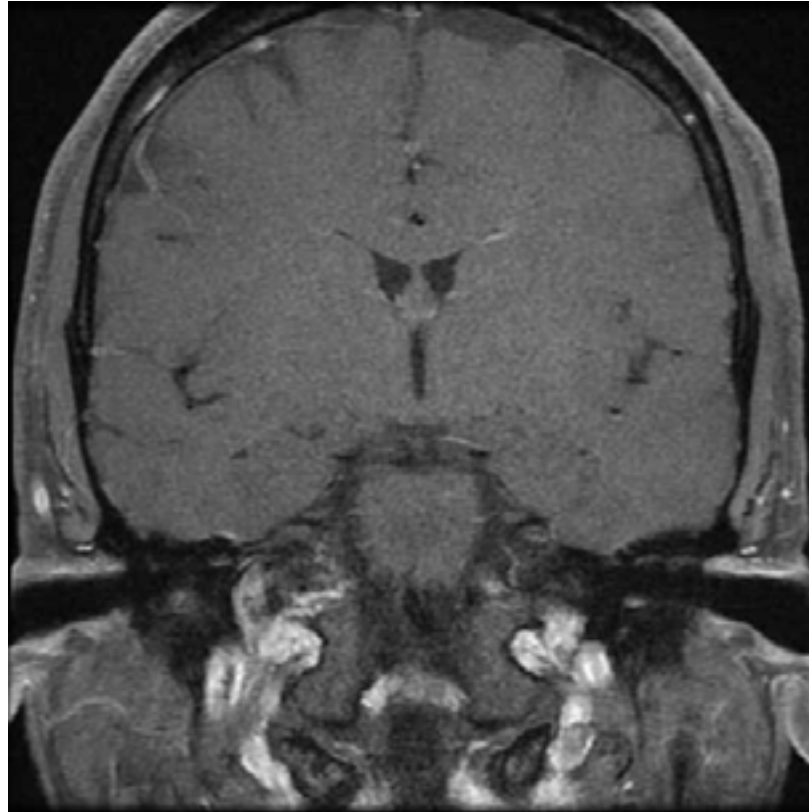


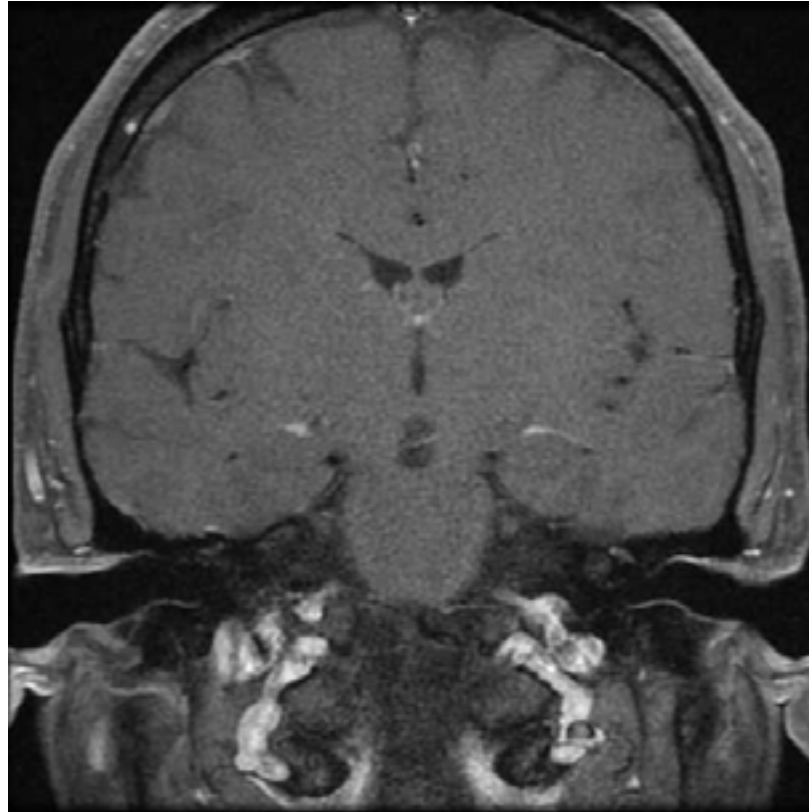


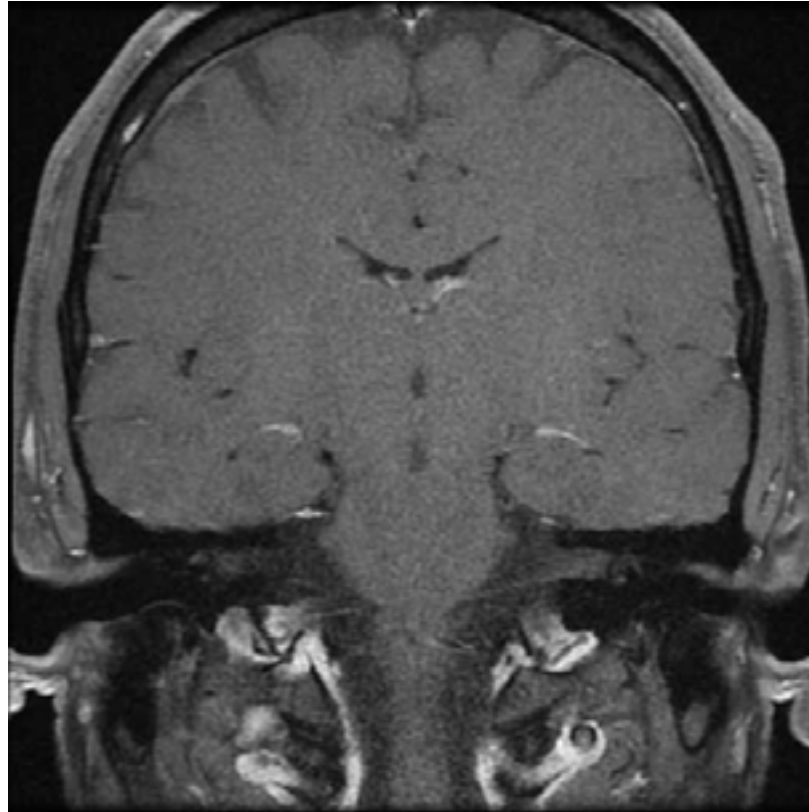


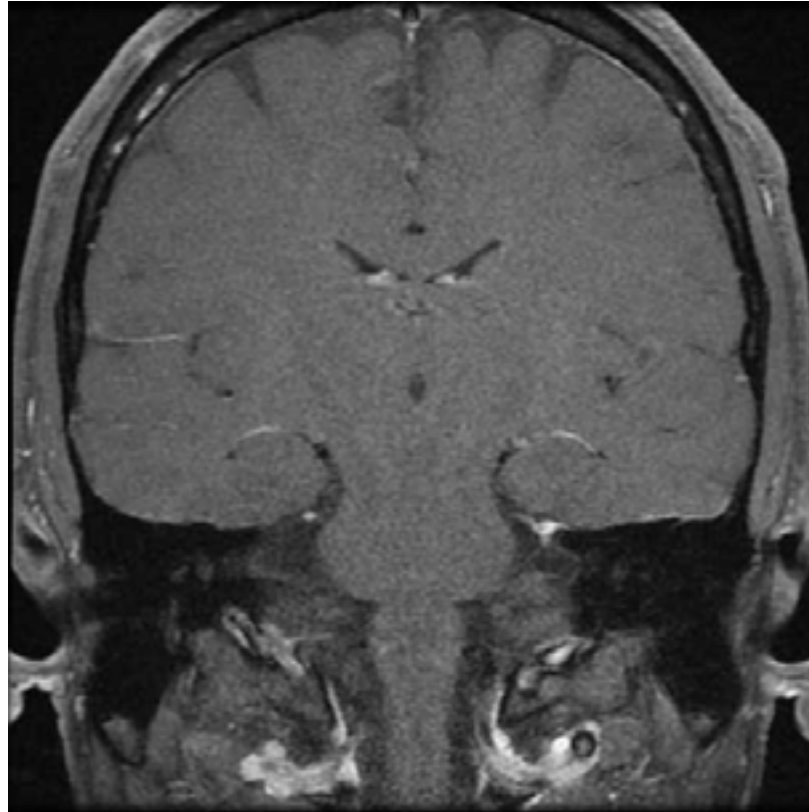




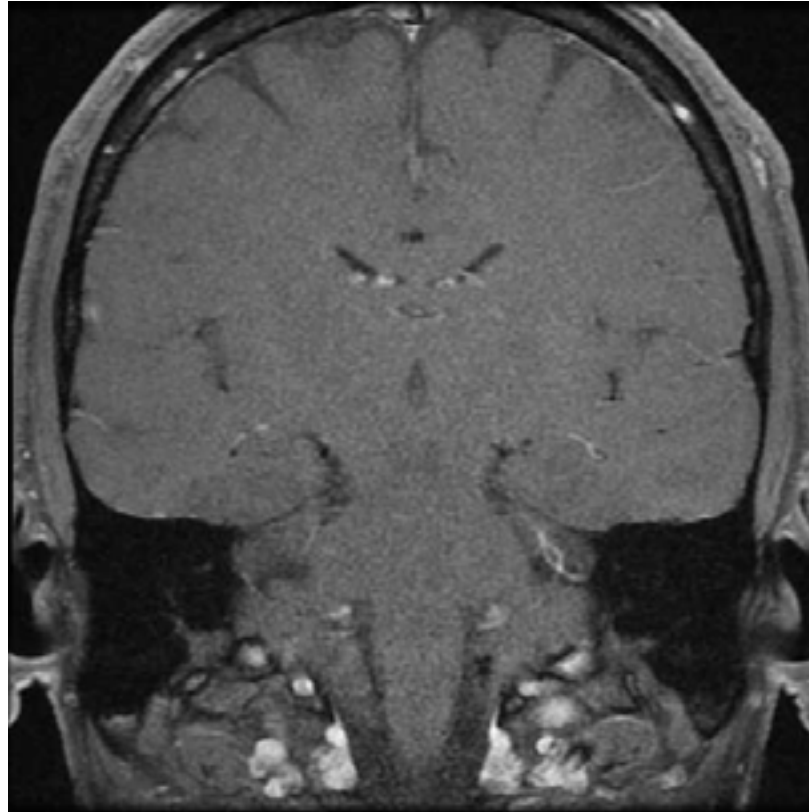


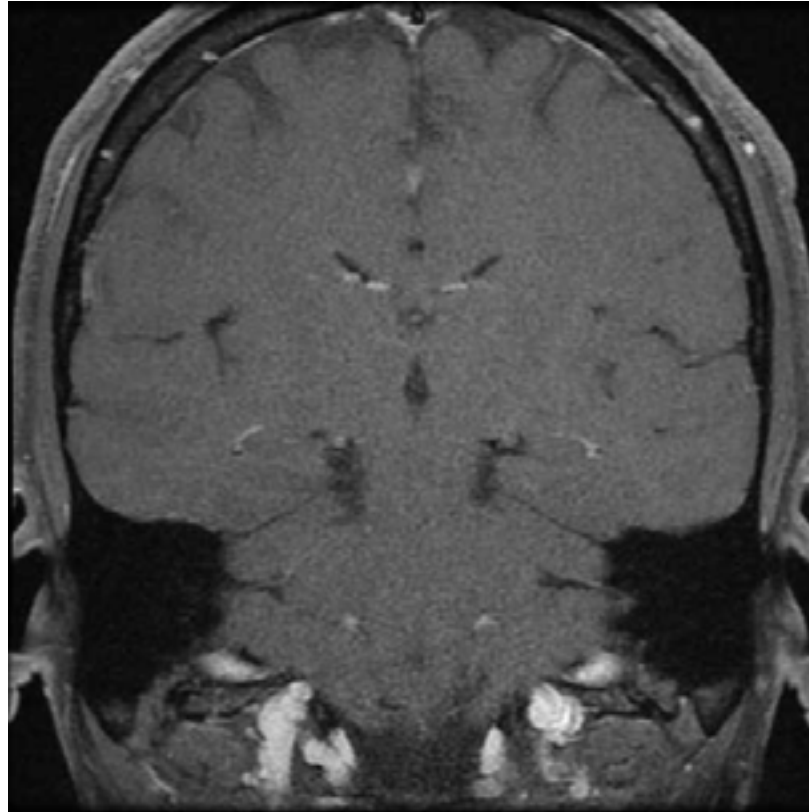


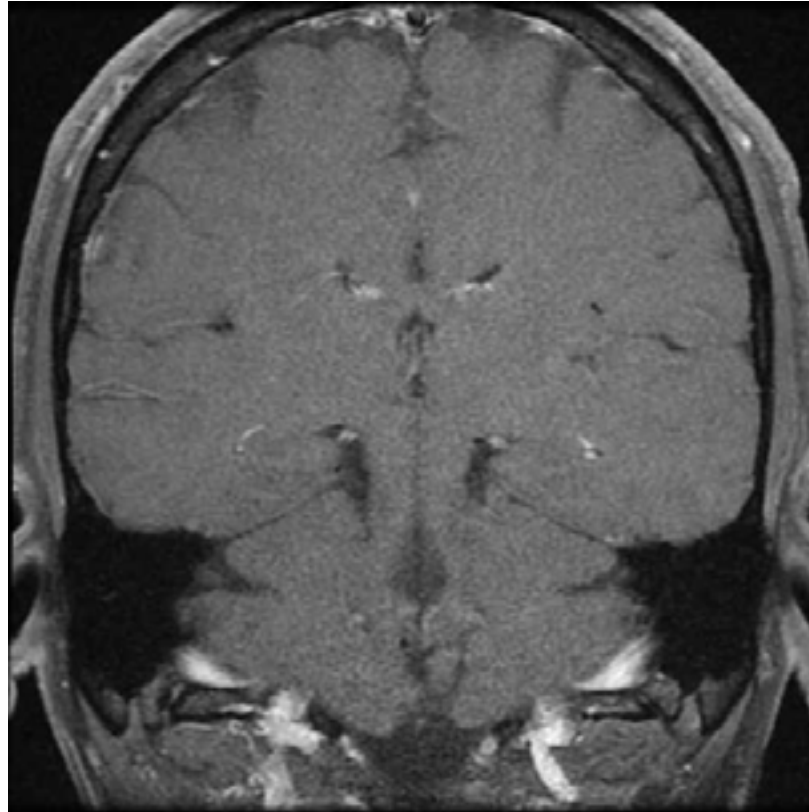


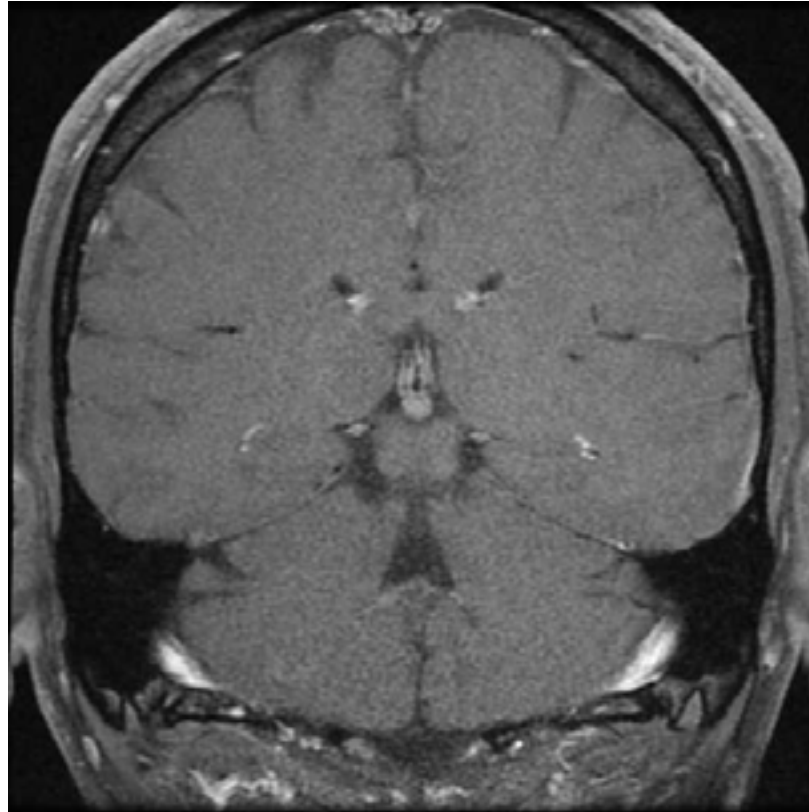




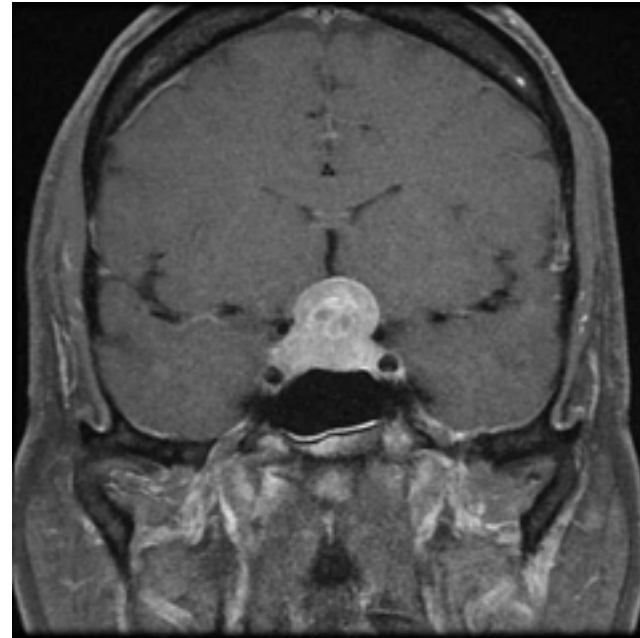
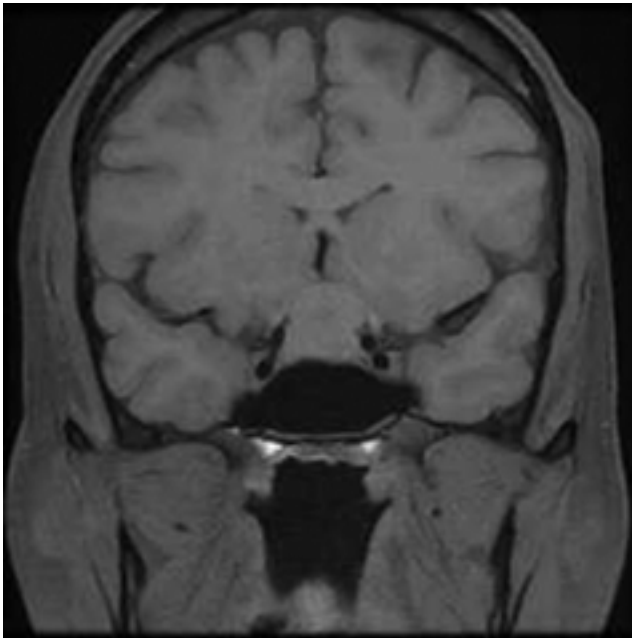


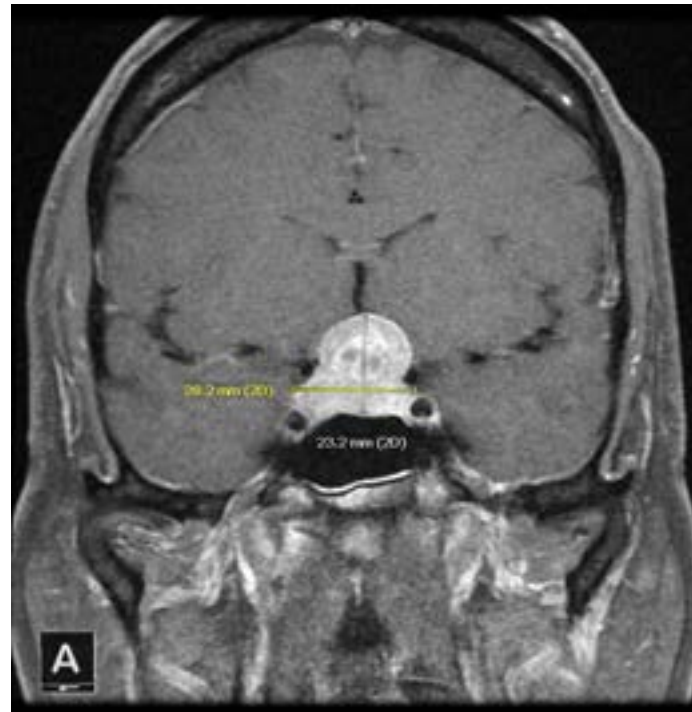






# Contrast vs. No Contrast








# MRI Report


Large 2.8 cm enhancing sellar/suprasellar mass consistent with a macroadenoma with a significant mass effect on the optic chiasm. There is possible invasion of the right cavernous sinus. Recommend neurosurgical consultation.

# OD Post-Surgical





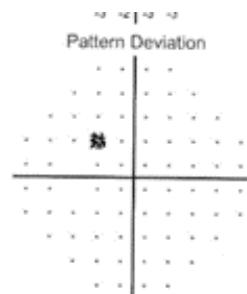
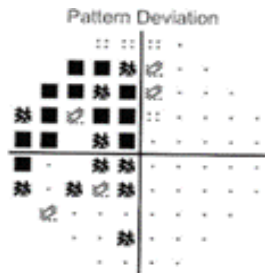
# OS Post-Surgical



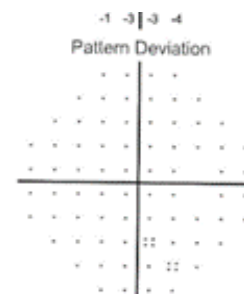
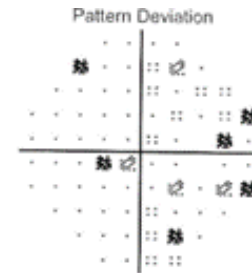


# Pre- vs. Post-surgical VFs

OS



OD





## PANEL DISCUSSION





# Pituitary Adenomas

These tumors are the **most common cause of chiasmal dysfunction in adults**, and they are **very common**, representing about **10–15% of all intracranial tumors**

About **70%** of pituitary adenomas occur in individuals **aged 30 to 50 years**, and only 3–7% occur in patients younger than 20 years

In general, they are **benign epithelial neoplasms** which **rarely metastasize**



# Pituitary Adenomas

Pituitary adenomas can be classified functionally by their endocrine abnormality into two major groups: those with nonfunctional enlargement and those exhibiting hormone hypersecretion

Approximately one-quarter to one-third clinically apparent pituitary adenomas are nonfunctioning or nonsecreting



# Pituitary Adenomas

- Since the chiasm is located directly above the pituitary in most instances, the crossing inferonasal fibers are usually the first to be disturbed by upward-growing adenomas, causing **superotemporal defects** respecting the vertical meridian
- **Acuity** is affected less commonly (estimated between **16–25%**) than visual fields
- **Disc pallor** occurs in about **30%** of patients



# Pituitary Adenomas

- In 80–95% of **microadenomas**, a hypointense lesion is evident within the normal pituitary on T1-weighted MRI
- MRI should be sufficient to outline vascular structures and rule out coexisting aneurysms, so routine angiography is unnecessary in most preoperative assessments



# Pituitary Adenomas

Optical coherence tomography (OCT) has demonstrated a strong relationship between **vision loss** and a decline in **RNFL thickness** in subjects with pituitary adenomas

**RNFL thinning** before treatment of these tumors is associated with a **poorer prognosis** for visual recovery





# Pituitary Adenomas


Except for prolactinomas, the first-line treatment of symptomatic adenomas is **transsphenoidal neurosurgery**

Access to the sphenoid is usually via a **sublabial** or **transnasal approach** or combinations of both

At some institutions, the sella is exposed transnasally or transseptally using an endoscope, and the tumor removal is accomplished also **endoscopically** or with an operating microscope



# Pituitary Adenomas



The prognosis for visual improvement is **excellent** following surgical or medical decompression



## Optical coherence tomography predicts visual outcome for pituitary tumors



Helen V. Danesh-Meyer<sup>a,d,\*</sup>, Aaron Wong<sup>a</sup>, Taras Papchenko<sup>a</sup>, Kaliopy Matheos<sup>a</sup>, Stanley Stylli<sup>c,d</sup>, Andrew Nichols<sup>c,d</sup>, Chris Frampton<sup>a</sup>, Mark Daniell<sup>e</sup>, Peter J. Savino<sup>b</sup>, Andrew H. Kaye<sup>c,d</sup>

<sup>a</sup>Department of Ophthalmology, Faculty of Medical and Health Sciences, The University of Auckland, Private Bag 52019, Auckland 1142, New Zealand

<sup>b</sup>Shiley Eye Centre, University of California San Diego, La Jolla, CA, USA

<sup>c</sup>Department of Neurosurgery, The Royal Melbourne Hospital, Parkville, VIC, Australia

<sup>d</sup>Department of Surgery, The University of Melbourne, The Royal Melbourne Hospital, Parkville, VIC, Australia

<sup>e</sup>Center For Eye Research Australia, East Melbourne, VIC, Australia

### ARTICLE INFO

#### Article history:

Received 29 January 2015

Accepted 7 February 2015

#### Keywords:

Optical coherence tomography

Pituitary tumor

Predictive outcome

Recovery

Vision

### ABSTRACT

We evaluate if the relationship between optical coherence tomography (OCT) of the retinal nerve fibre layer (RNFL) and visual outcome continued over long-term visual recovery in 107 patients undergoing pituitary decompression. Recently, it has been recognized that OCT of the RNFL has prognostic value in predicting visual outcomes after surgery for chiasmal compression caused by pituitary tumours. Patients were followed up at three time points: pre-operative (visit 1), 6–10 weeks post-operative (visit 2) and 9–15 months follow-up (visit 3). We found that patients with thin pre-operative RNFL had more severe visual field defects (mean deviation [MD] –9.22 versus –3.96 decibels [dB];  $p = 0.001$ ), but pre-operative visual acuity (VA) was good in both normal and thin RNFL groups (Snellen VA 6/5 and 6/4;  $p = 0.039$ ). For those with thin RNFL the greatest improvement was between visit 2 and 3 (MD –7.1 dB versus –3.4 dB, respectively;  $p < 0.001$ ) compared with pre-operative –9.8 dB. Normal RNFL patients showed greatest improvement between visits 1 and 2 (pre-operative –4.8 dB, visit 2 –2.0 dB, visit 3 –0.9 dB;  $p = 0.001$ ). For long-term follow-up, 81.0% of eyes with normal RNFL, compared to 37.1% with thin RNFL ( $p < 0.001$ ), achieved an MD of –2.00 dB (final visit). At final follow-up, 97.5% of normal RNFL eyes achieved VA of 6/12 or better compared with 88.2% with thin RNFL ( $p = 0.034$ ). Our results indicate that long-term visual recovery after surgical decompression of pituitary lesions is predicted by pre-operative OCT RNFL. Patients with normal RNFL thickness show an increased propensity for visual recovery. This effect continues after long-term follow-up, however, most visual recovery occurs within the first 6–10 weeks.

© 2015 Elsevier Ltd. All rights reserved.

With surgical intervention, we expect significant improvement in visual function.

A delay in treatment could worsen visual prognosis.

OCT is very helpful in predicting visual outcome, and can help in determining urgency.

Danesh-Meyer HV, Wong A, Papchenko T, et al. Optical coherence tomography predicts visual outcome for pituitary tumors. *Journal of Clinical Neuroscience*. 2015;22(7):1098–1104



10.68(2):346-351. doi: 10.4103/0028-3886.280634

## An Analysis of Retinal Nerve Fiber Layer Thickness before and after Pituitary Adenoma Surgery and its Correlation with Visual Acuity

Mohd Iqbal<sup>1</sup>, Sumaiya Irfan<sup>2</sup>, Jawahar L Goyal<sup>3</sup>, Daljit Singh<sup>4</sup>, Hukum Singh<sup>4</sup>, Gautam Dutta<sup>4</sup>

Affiliations + expand

PMID: 32189695 DOI: 10.4103/0028-3886.280634

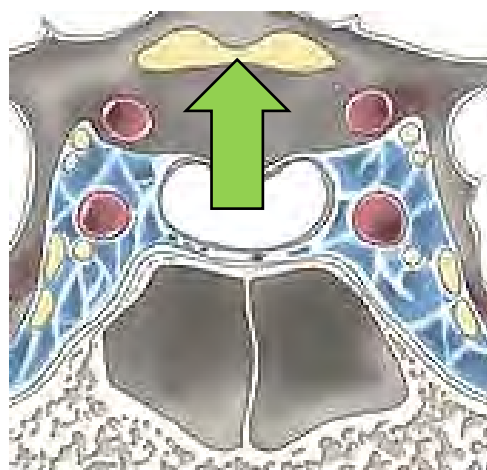
**Introduction:** Pituitary adenomas comprise approximately 10% of all intracranial tumors. Initially, subtle changes occur in the field of vision, which are difficult to assess clinically. It has been seen that following surgery of pituitary macroadenoma, total recovery of normal vision occurs in 35% of the patients, improvement of vision occurs in 60%, and in the rest there is no change in vision. Retinal nerve fiber layer thickness (RNFLT) undergoes retrograde degeneration following compression of optic apparatus by pituitary tumor. We planned a study to evaluate RNFLT before and after pituitary adenoma surgery and its correlation with visual acuity.

**Material and methods:** Twenty patients (40 eyes) with diagnosed pituitary adenoma were included in the study. Preoperative visual acuity, fundus and RNFL thickness were calculated using spectral-domain OCT Optovue, Heidelberg Engineering, Heidelberg, Germany (RT 100 version 5.1), and postoperative measurement was done after 1 and 3 months. Four-quadrant mean of RNFLT was calculated. Results were tabulated and analyzed.

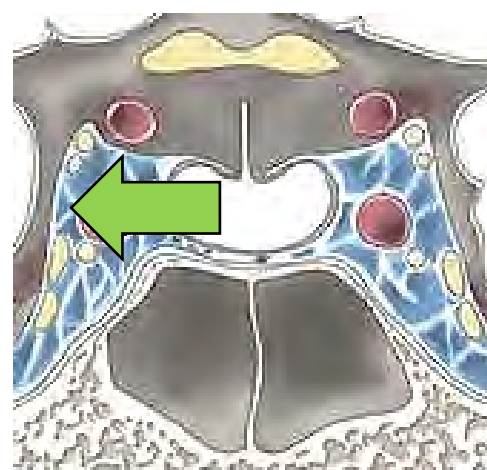
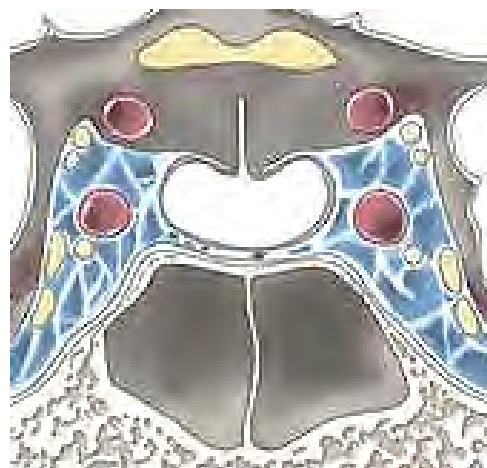**Statistical analysis:** Results of the study were analyzed using IBM SPSS Statistics version 19.0.

**Results:** There was no significant change in RNFLT after pituitary adenoma surgery, and it was found that patients with RNFLT within normal range preoperatively showed improvement in visual acuity after pituitary surgery. On the other hand, patients who had thinned-out RNFLT preoperatively showed no improvement in visual acuity. It was also found that once optic disc pallor sets due to chronic compression, then chances of its reversion to normal depend on its grading: only mild pallor disc has some chance to revert to normal, whereas moderate and severe pallor do not revert to normal.

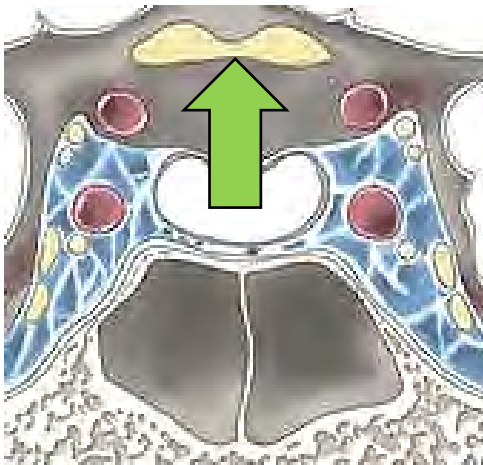
**Conclusion:** RNFLT and optic disc can be used as prognostic factors for evaluation of visual outcome in pituitary adenoma surgery.



- **AFFERENT VISUAL SYSTEM EFFECTS**



- **EFFERENT VISUAL SYSTEM EFFECTS**



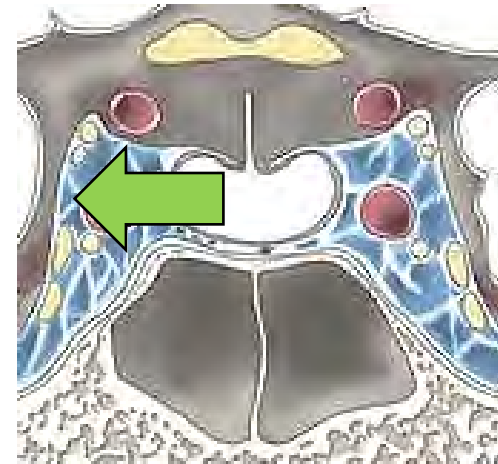
- **AFFERENT VISUAL SYSTEM EFFECTS**

Vision loss  
Reduced visual acuity  
Visual field loss  
Dyschromatopsia  
Relative afferent pupillary defect possible



Diplopia  
Ocular misalignment  
Cranial nerve III, IV, VI palsies

It is important to  
assess for efferent  
manifestations of  
pituitary  
adenomas!



- **EFFERENT VISUAL  
SYSTEM EFFECTS**





# Pituitary Tumors are **RARE** in **CHILDREN**

- Only 3% of all pediatric intracranial tumors
- When they do occur in kids, **they are more likely to be secreting (functional) tumors**
- Pituitary functions are important!







# CRANIOPHARYNGIOMA in KIDS

- most common suprasellar brain tumor in children
- most common tumor associated with severe permanent visual impairment in children
  - 30% present with vision loss
  - 30% experience visual decline after initial diagnosis & tx
    - Need to watch closely even after treatment
  - Visual acuity loss and optic atrophy are common
  - 58% visual impairment in at least one eye
  - 10% being legally blind in both eyes



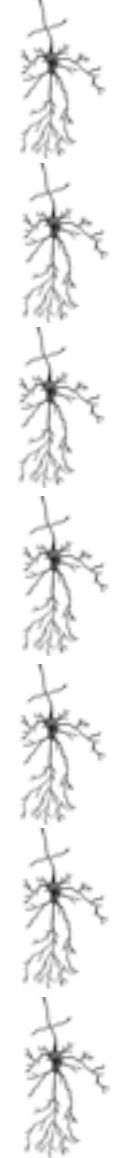

# Not Every Pituitary Adenoma Needs Surgery

But, we should co-manage all of them with neurosurgery.

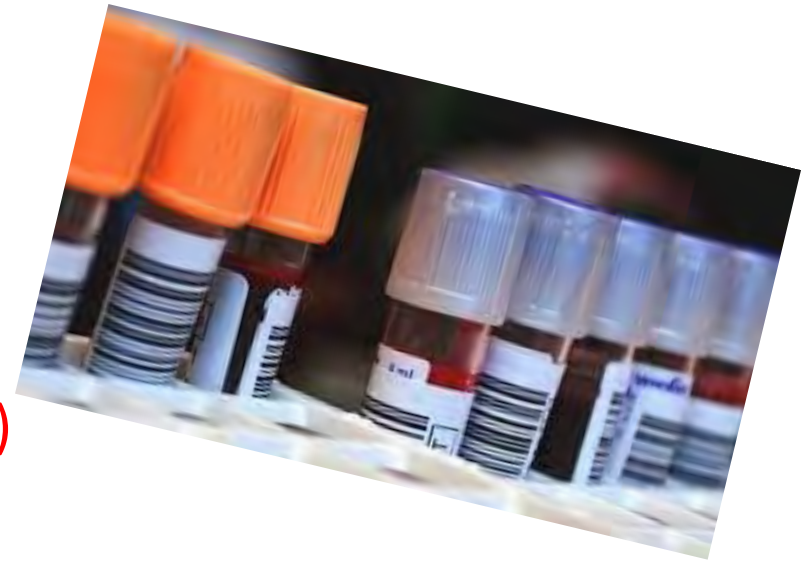If there is no vision loss, patient is asymptomatic, there is no significant chiasmal compression and labs are normal, sometimes the management plan involves only surveillance.

- Interval MRIs
- Interval VFs
- Interval OCTs





# Pituitary Function Tests



- Prolactin
- AM Cortisol
- ACTH (adrenocorticotrophic hormone)
- IGF-1 (insulin-like growth factor 1)
- GH (growth hormone)
- TSH (thyroid stimulating hormone), fT4
- LH, FSH (luteinizing hormone, follicle stimulating hormone)
- Testosterone / Estrogen



# Types of Secretory or Functional Pituitary Adenomas

- **Prolactin-secreting pituitary adenoma (Prolactinoma)**
  - Women: loss of menstrual periods and breast milk production
  - Men: lower testosterone levels, leading to diminished sexual interest
- **Growth hormone-secreting pituitary adenoma**
  - An excessive production of growth hormone (GH) causes enlarged hands and feet and other changes in the body
    - Acromegaly in adults
    - Gigantism in children
- **ACTH-secreting pituitary adenoma**
  - Excessive ACTH hormone production causes Cushing's disease.
  - Symptoms include unexpected weight gain, easy bruising of skin muscle, weakness
- **TSH-secreting pituitary adenoma (Thyrotropinoma)**
  - Excessive TSH hormone production leads to hyperthyroidism.
  - very rare



# PROLACTINOMA

## SYMPTOMS:

**AMENORRHEA** (absence of menstruation)

**GALACTORRHEA** (discharge from breasts)

**INFERTILITY** (anovulation)

**GYNECOMASTIA** (swelling of male breast tissue)

**DECREASED LIBIDO** (sexual desire)

**IMPOTENCE**



## ***TREATMENT OF PROLACTINOMAS***

### ***MEDICAL TREATMENT***

#### **DOPAMINERGIC AGONISTS**

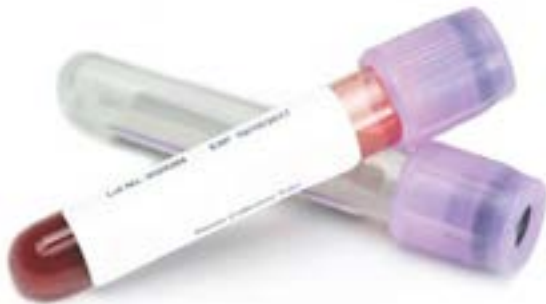- Reduce Prolactin Synthesis
- Decrease Size of Prolactinoma
  - **BROMOCRIPTINE** (ERGOSER, PARLODEL)
  - **CABERGOLINE** (DOSTINEX)
  - **PERGOLIDE** (PERMAX)

Need to get pituitary function tests before deciding on treatment of pituitary adenomas.

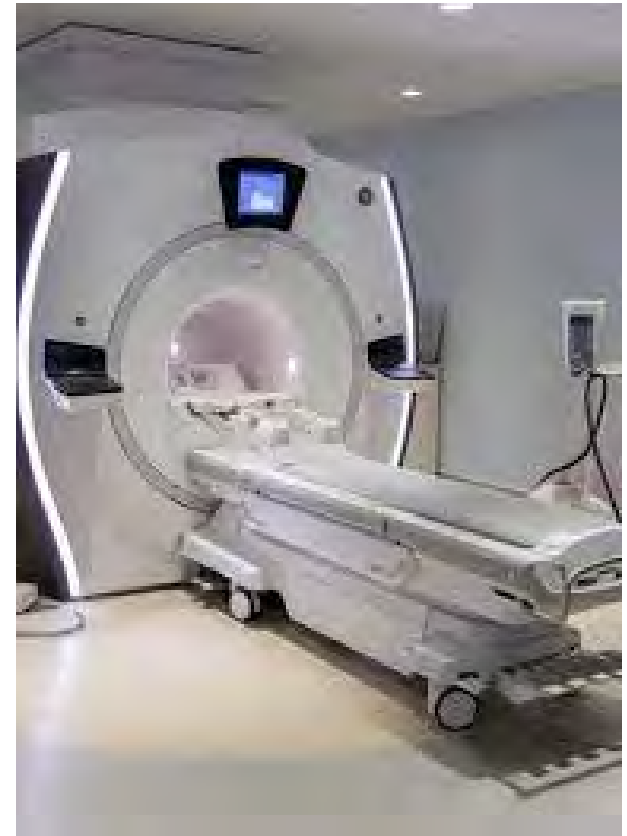You should get the labs prior to patient seeing neurosurgery, so they have all the necessary data to make a treatment decision.



Both imaging and pituitary function lab testing should be obtained prior to the neurosurgical consult (except in emergent cases).



\* Random cortisol and ACTH if possible





# Pituitary Apoplexy

**PITUITARY APOPLEXY**  
Sudden infarct in, or bleed  
of pituitary adenoma

## Hemorrhagic and ischemic

Occurs in 0.6-10% of new pituitary adenomas

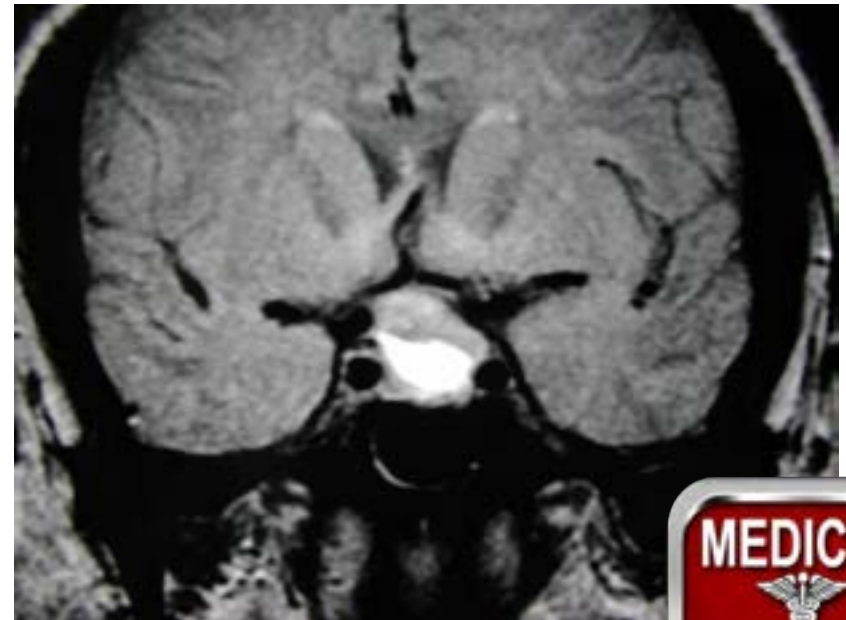Up to 2% of previously treated adenomas

PANHYPOPITUITARISM...  
LOSS OF GH, ACTH, LH, FSH,  
Prolactin, TSH  
(all produced in anterior pituitary)

*ADRENAL FAILURE CAN LEAD TO  
SHOCK AND DEATH*

*VISION LOSS FROM MASS EFFECT*

*SUB-ARACHNOID HEMORRHAGE*







## PITUITARY APOPLEXY Clinical Syndrome

- **SUDDEN HEADACHE, NAUSEA, EMESIS**
- **VISUAL LOSS**
- **OPHTHALMOPLEGIA (Cavernous sinus involvement)**
- **FEVER**
- **STIFF NECK (sub-arachnoid hemorrhage)**
- **HORMONE INSUFFICIENCY**

Not every case is textbook. Can be partial and more insidious.



We need to carefully assess for visual field defects and ocular motility abnormalities in all patients, whether or not they are symptomatic!



# Stroke Background Information











# Stroke

- 80% of strokes are preventable!!
- 1/5 die within a year of 1<sup>st</sup> stroke
  - Deaths from stroke are dropping due to development of regional stroke centers
- Know where the stroke center(s) is/are in your area!
- Ask your patients about stroke symptoms
  - Both ocular and non-ocular
- Measure BP and pulse regularly

# Beyond F.A.S.T. – Other Symptoms You Should Know

<b>B</b>	<b>E</b>	<b>F</b>	<b>A</b>	<b>S</b>	<b>T</b>
<b>Balance</b>	<b>Eyes</b>	<b>Face</b>	<b>Arms</b>	<b>Speech</b>	<b>Time</b>
					
<b>B is for Balance:</b> Does the person have a sudden loss of balance?	<b>E is for Eye:</b> Has the person lost vision in one or both eyes?	<b>F is for Face:</b> Does the person's face look uneven?	<b>A is for Arm:</b> Is one arm hanging down?	<b>S is for Speech:</b> Is the person's speech slurred? Does the person have trouble speaking or seem confused?	<b>T is for Time:</b> Call 911 now!



# Role of Optometrists

- Preventative Measures
  - Identify stroke risk factors
  - Educate patients
  - Refer as necessary
- Identify Acute Stroke / TIA
  - Get patient immediate (emergent) work-up/treatment as necessary
- Determine if Deficits are from old strokes or if they indicate a new stroke/other process (localization)
- Assess visual function after stroke
  - Improve visual function where possible
  - Comment on driving ability



# Location of stroke (infarct)

## ■ Anterior Circulation

- ◆ Carotid artery
- ◆ Anterior cerebral artery
- ◆ Middle cerebral artery

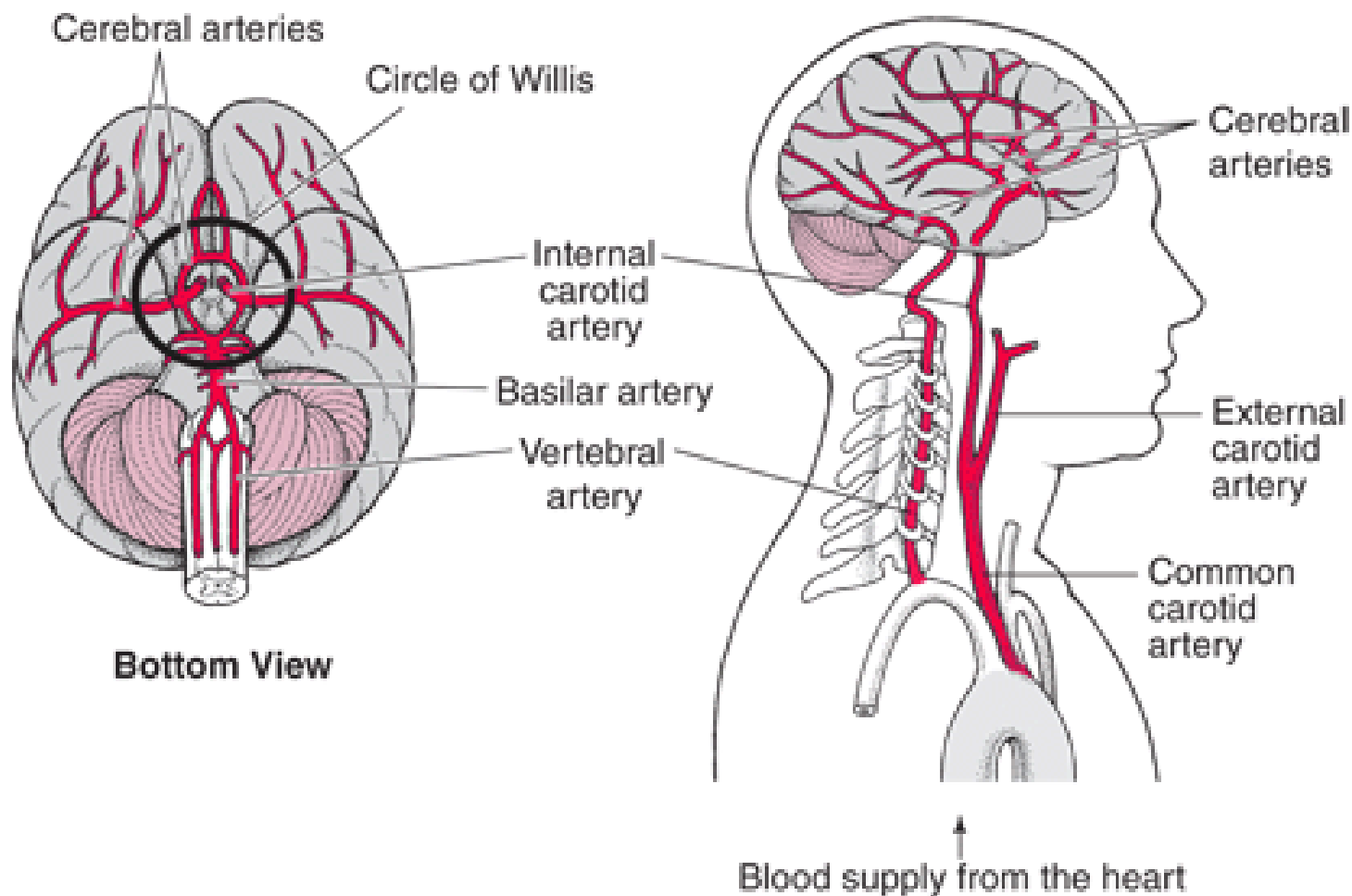
## ■ Posterior Circulation

- ◆ Vertebro-basilar
- ◆ Posterior cerebral artery



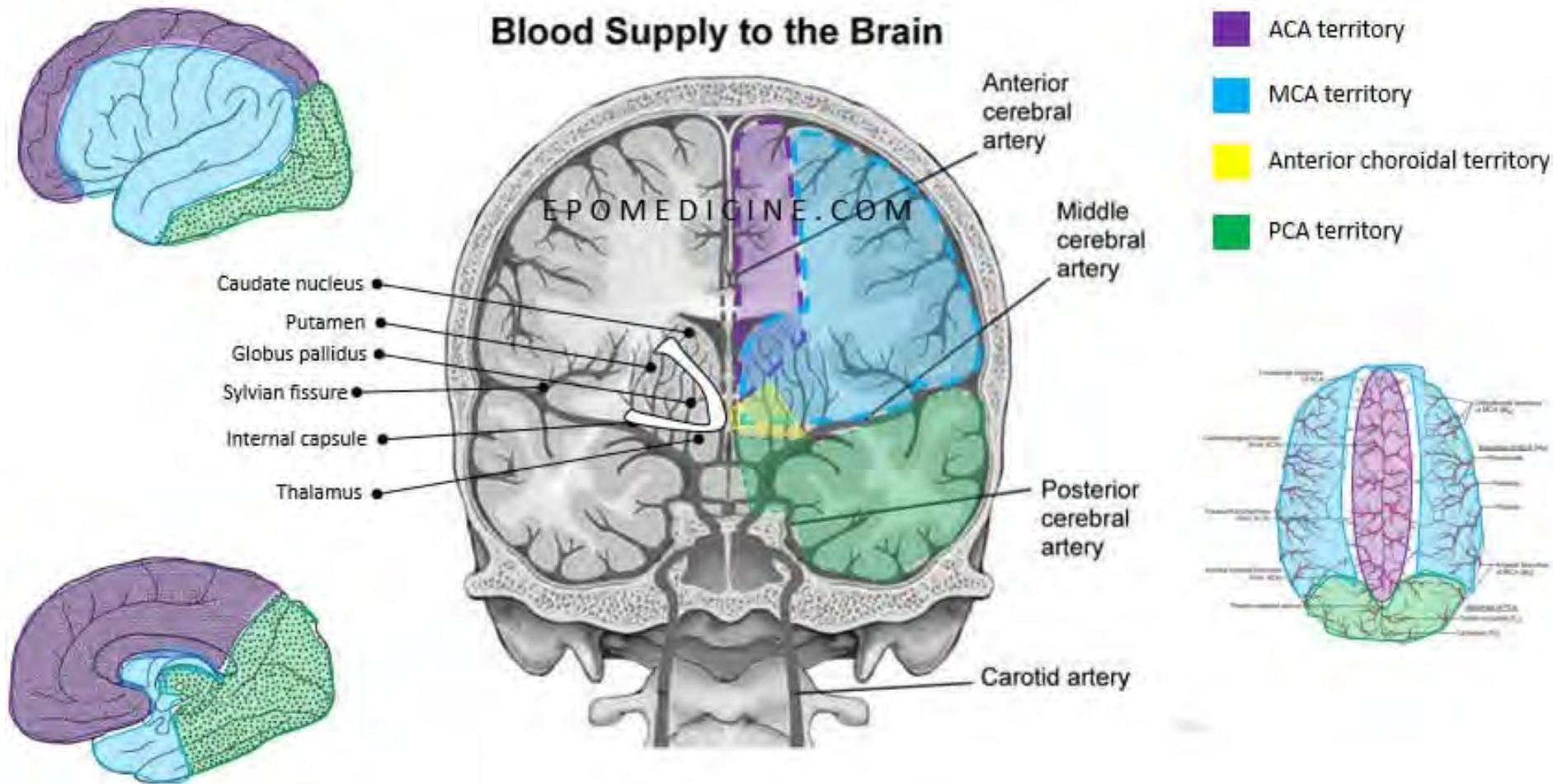
The location of the involved circulation/infarct determines the clinical presentation  
(Remember: Not everyone's anatomy is the same! – can have variants)

Knowing the anatomy and its corresponding function is key to stroke localization





# Blood Supply to the Brain

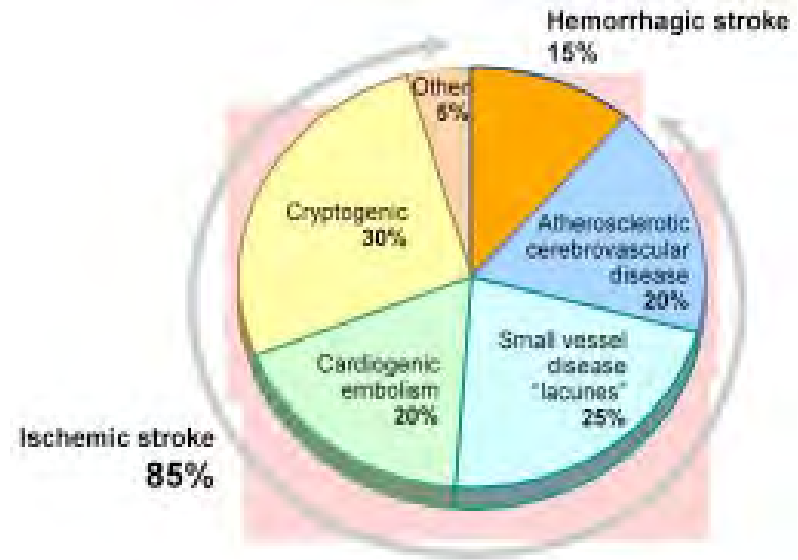


<https://radiopaedia.org/articles/brain-arterial-vascular-territories?lang=us>

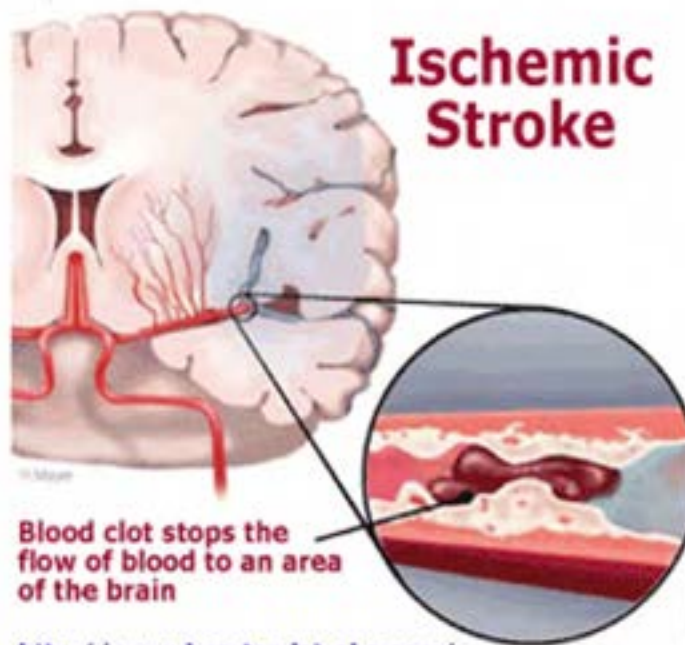
# TYPES OF STROKE

## Etiology

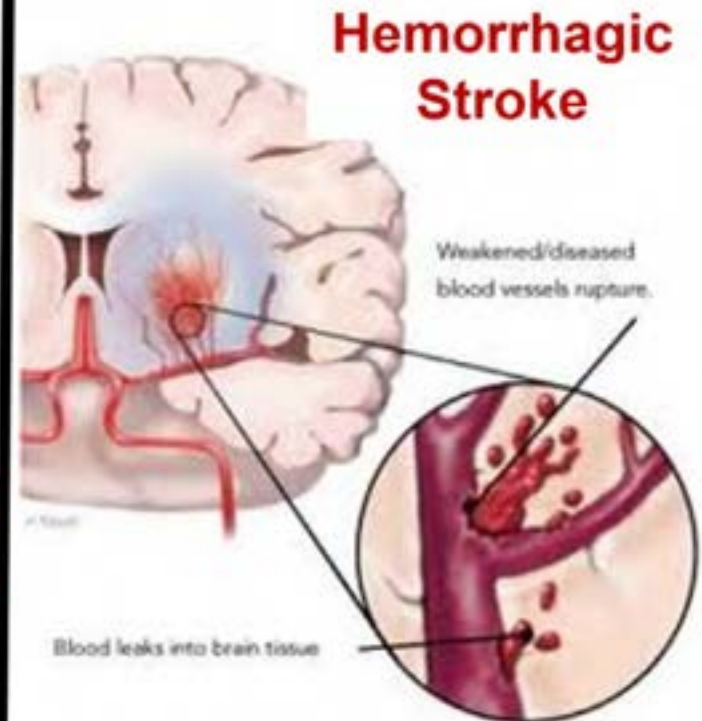
- **Ischemic (80-85%)**
  - Thrombosis
  - Embolism
- **Hemorrhagic (15%)**



Albers et al. Chest 2004; 126 (3 Suppl): 430S-512S.



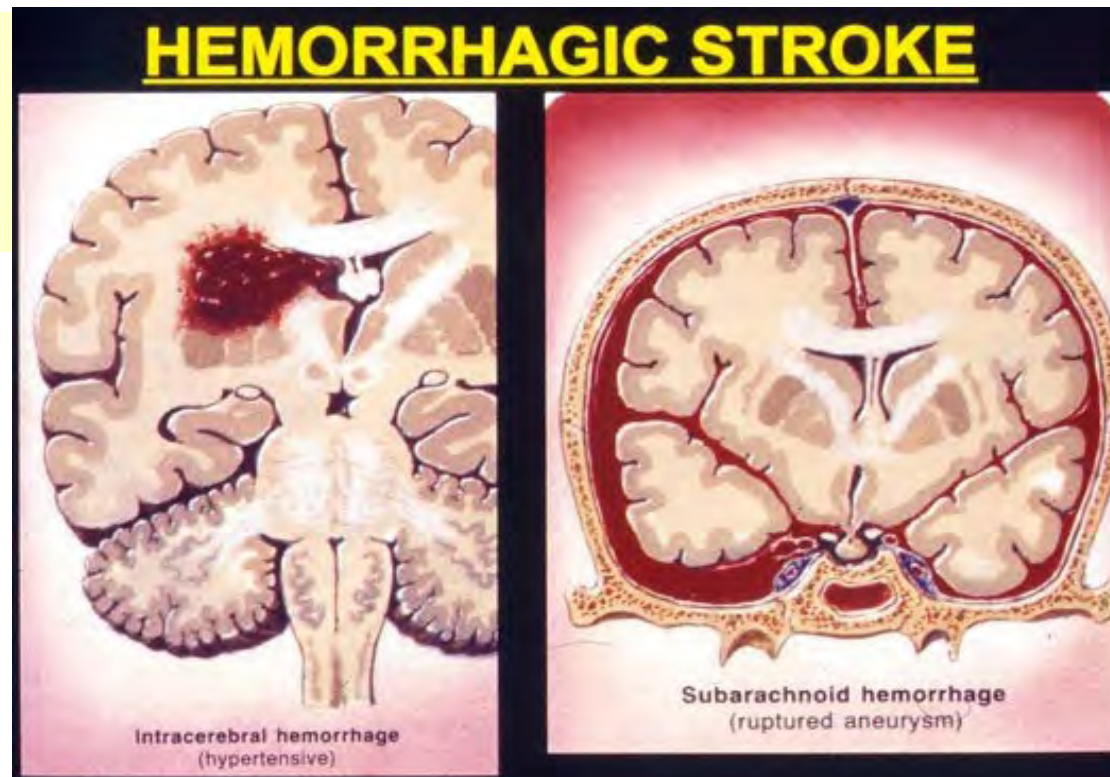
<http://www.heartandstroke.com/>  
©Heart and Stroke Foundation of Canada



©Heart and Stroke Foundation of Canada

# Hemorrhagic Stroke

- Intracerebral Hemorrhage
  - ◆ Hypertension
- Sub-arachnoid Hemorrhage
  - ◆ Ruptured aneurysm
- More likely present with symptoms of increased ICP
  - ◆ Nausea
  - ◆ Vomiting
  - ◆ Headache
  - ◆ Change in consciousness

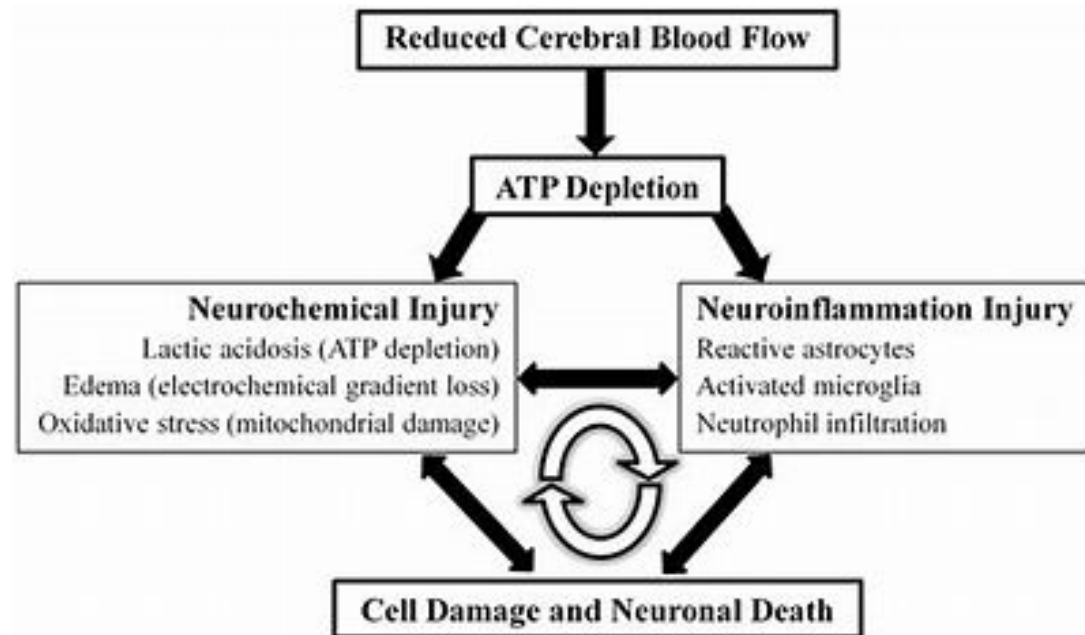
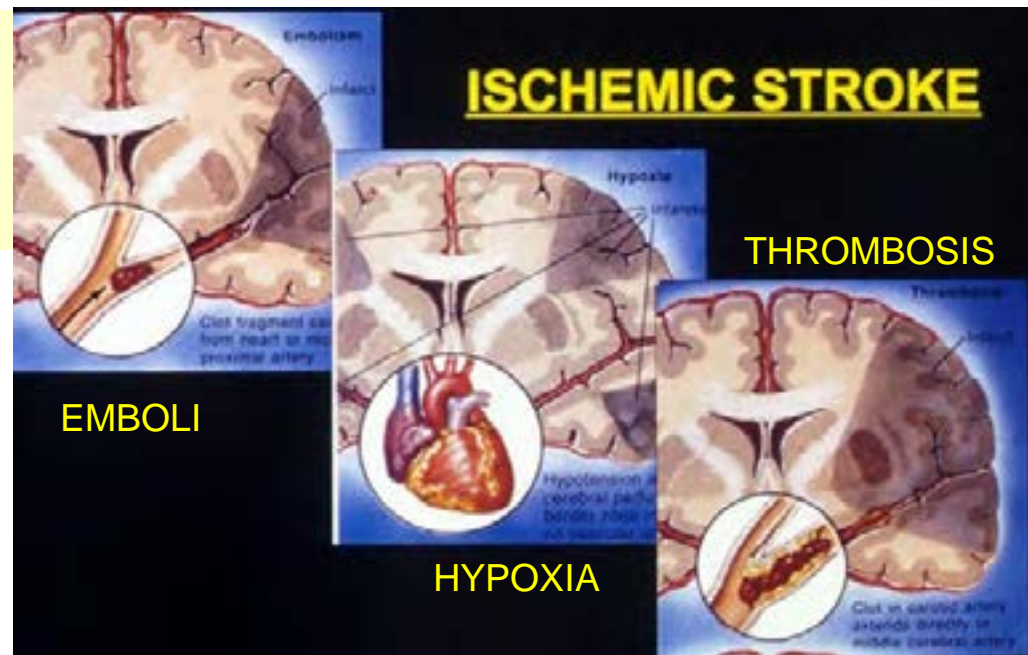


- STAT head CT in ER to identify Hemorrhagic stroke
  - Treatment
    - ◆ Evacuation of the hemorrhage - Craniotomy
    - ◆ Observation (if small)



# ISCHEMIC STROKE

- When an ischemic stroke occurs, the **blood supply to the brain is interrupted**, and **brain cells are deprived of the glucose and oxygen they need to function.**
- Within minutes, brain cells begin to die
- The ischemic area involved determines the type of focal deficit that is seen in the patient



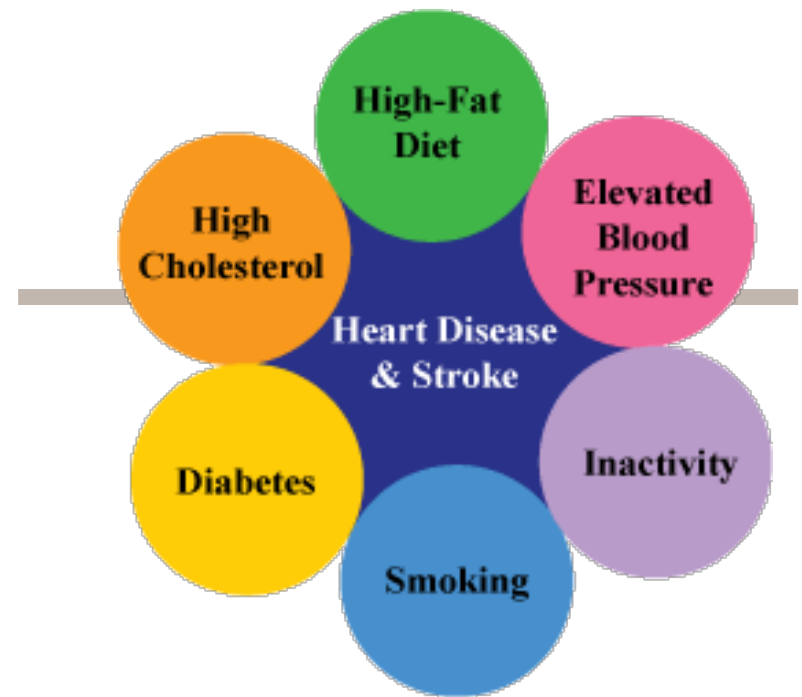


# Ischemic Stroke

- **From Emboli**
  - Mitral stenosis
  - Endocarditis
  - Myocardial infarction
  - Patent Foramen Ovale
  - Congestive Heart Failure
  - Atrial Fibrillation
- **From Thrombus**
  - Arterial stenosis
    - Atherosclerosis
  - Sickle cell anemia
  - Protein C deficiency
  - Hyperhomocysteinemia
  - Other hypercoagulable state

# Other Ischemic Stroke Risk Factors

- Hypertension
- Diabetes
- Hypercholesterolemia
- Tobacco Use
- Sleep Apnea
- Poor Diet
- Lack of exercise



Educate!

# Stroke Prevention



We have a responsibility to educate patients about stroke prevention!

# Stroke Work-Up

## □ Acute Stroke

### ▣ To ER (with stroke center) ASAP

#### ■ **Neuroimaging** - brain

- CT – r/o hemorrhagic stroke
- MRI with DWI and ADC

#### ■ **Vascular imaging**

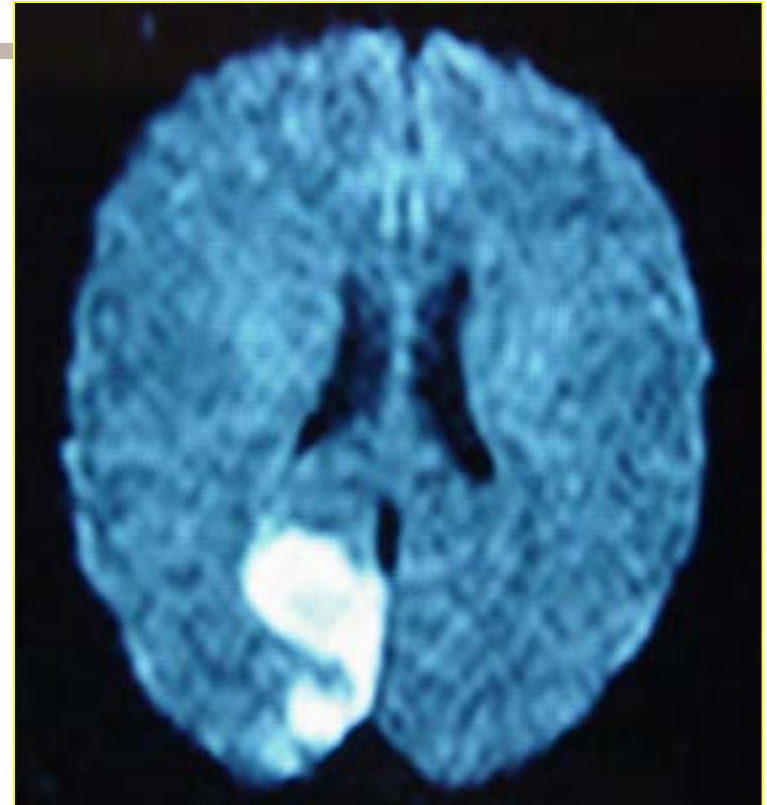
- CTA/MRA – look at blood flow
- Carotid Doppler US

#### ■ **Cardiac evaluation**

- EKG
- Echocardiogram
  - Trans-thoracic (TTE)
  - Trans-esophageal (TEE)

#### ■ **Labs**

- CBC, chem panel, hypercoagulable states, lipid panel, homocysteine, ESR, C-reactive protein, platelet count, (r/o GCA) etc.







# CASE 3

## Stroke





# 67 year-old man

History of blindness OD x 7 yrs (RD)

HTN, hypercholesterolemia, gout

Meds: Diovan, indomethacin (ASA d/c c indo)

1-2 weeks ago noted sudden decreased vision OS

Seemed to be temporally OS

Some shortness of breath

No associated pain or other neuro symptoms (denies GCA symptoms)

Vision improved somewhat in first day, but stable since

Saw PCP – did EKG – normal

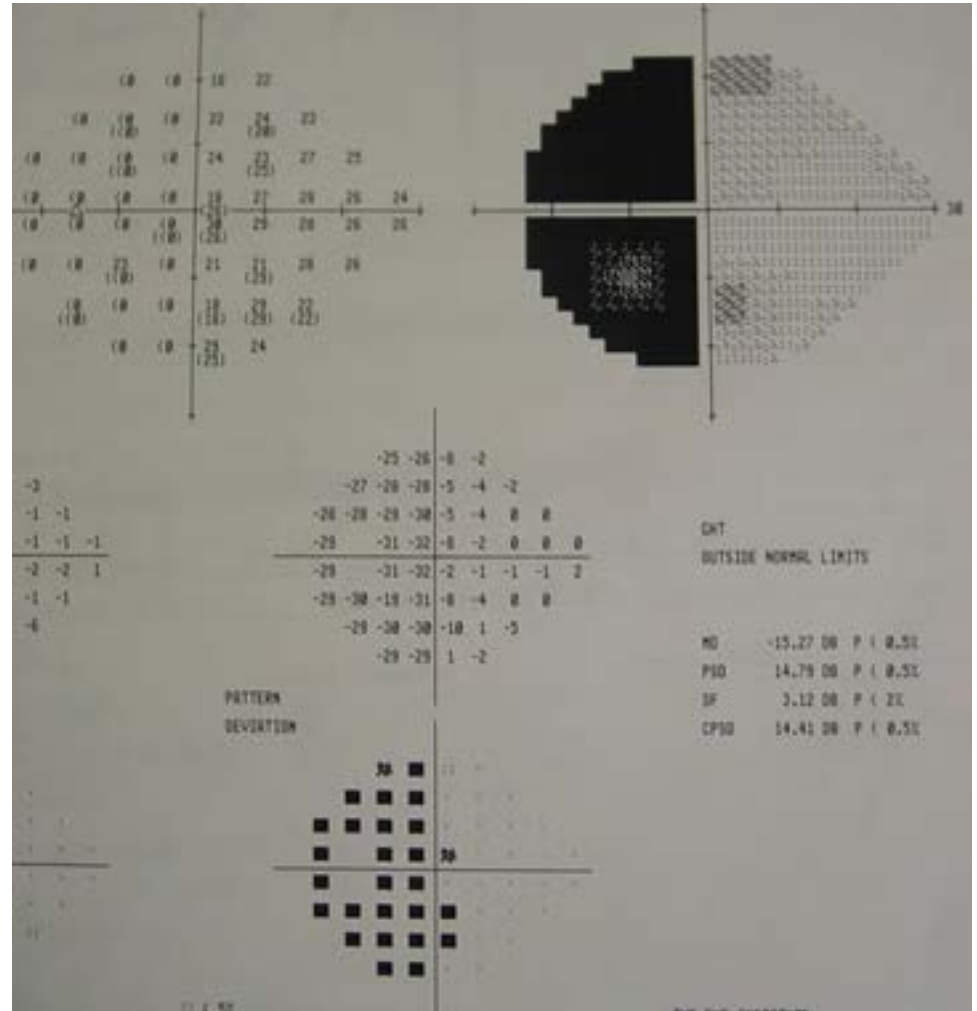
Pt refused stress test

## EXAM RESULTS

- VA OD NLP OS 20/25
- (+) RAPD OD
- BP 160/100
- Neurologic-exam:
  - Finger-to-nose ataxia
  - Difficulty with tandem gait

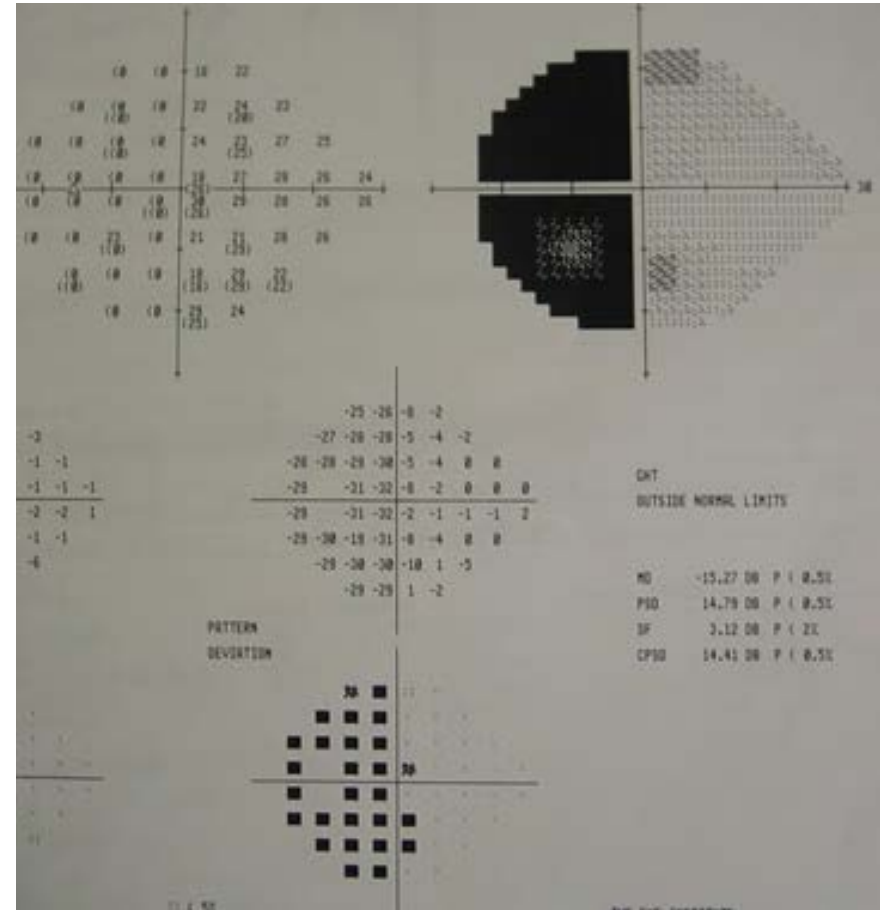
What do we think about this VF?

What could it indicate? 2 possibilities



## EXAM RESULTS

- VA OD NLP OS 20/25
- (+) RAPD OD
- BP 160/100
- Neurologic-exam:
  - Finger-to-nose ataxia
  - Difficulty with tandem gait



# Bitemporal vs Homonymous





# Sudden Vision Loss

- Bitemporal Hemianopia
    - PITUITARY APOPLEXY
      - Sudden infarct in or bleed of pituitary adenoma
        - Headache
        - Nausea
        - Vomiting
        - Vision loss
        - Can effect EOMS (cavernous sinus)
        - Hormone insufficiency
  - Painful (usually)
- Homonymous Hemianopia
    - RETROCHIASMAL STROKE
      - Ischemic or hemorrhagic stroke
        - Optic tract
        - Lateral geniculate nucleus
        - Optic radiations
        - Occipital lobe (purely vision)
  - Painless (usually)



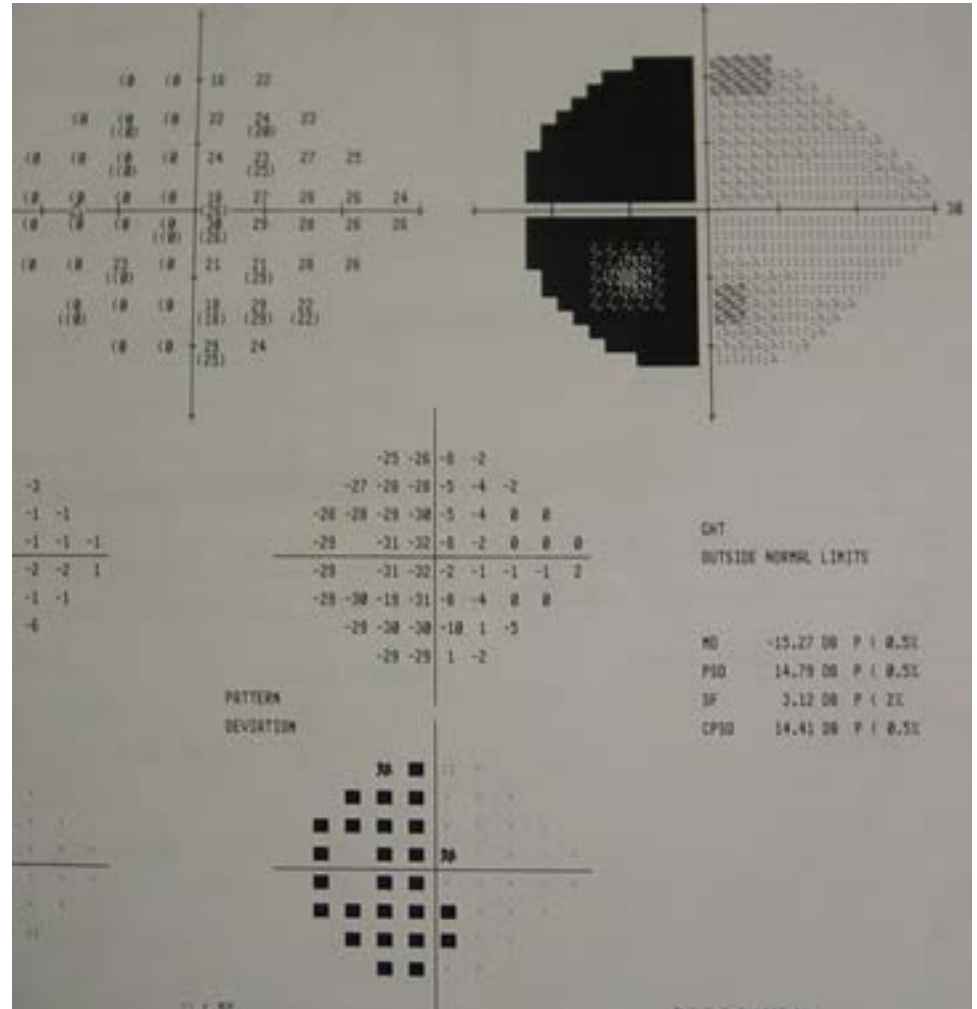
## EXAM RESULTS

- VA OD NLP OS 20/25
- (+) RAPD OD
- BP 160/100
- Neurologic-exam:
  - Finger-to-nose ataxia
  - Difficulty with tandem gait

Where does this localize?

What do we need to do?

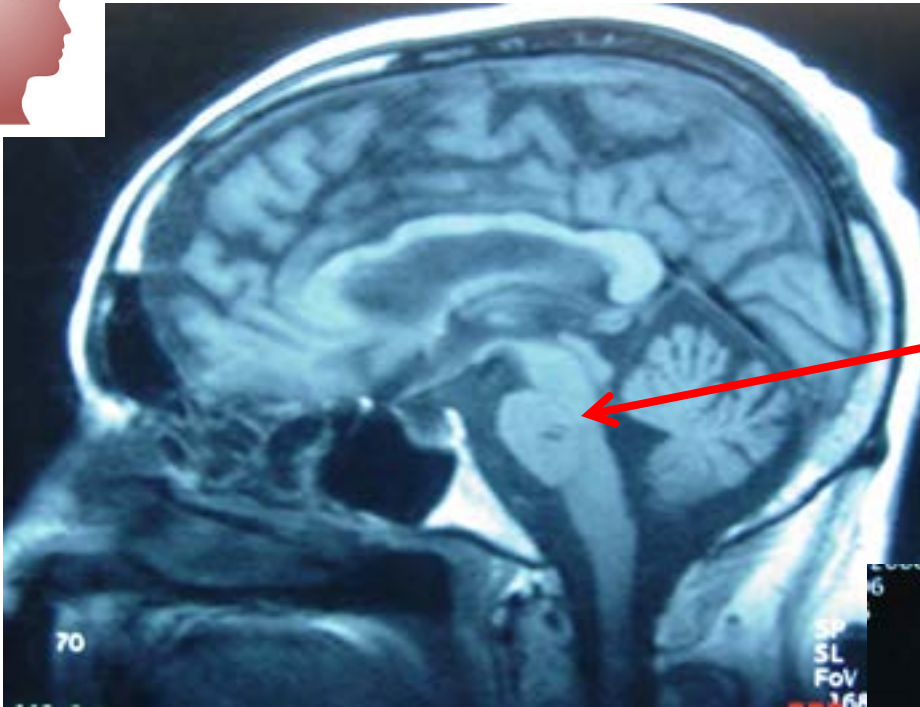
How urgent is this?



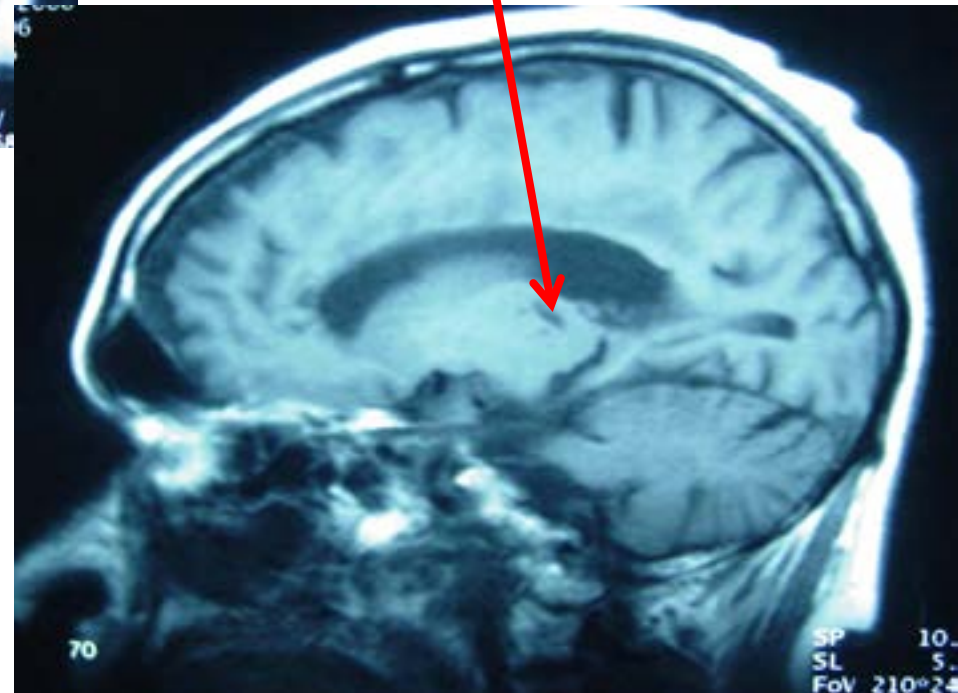


# Neuroimaging!!

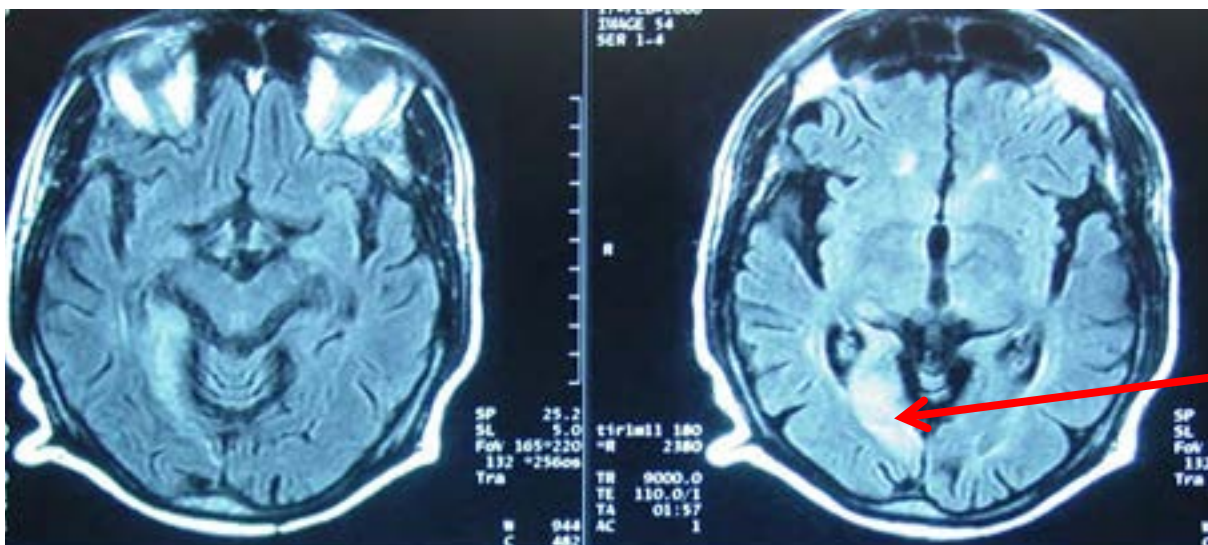
MRI brain without contrast  
MRA head without contrast



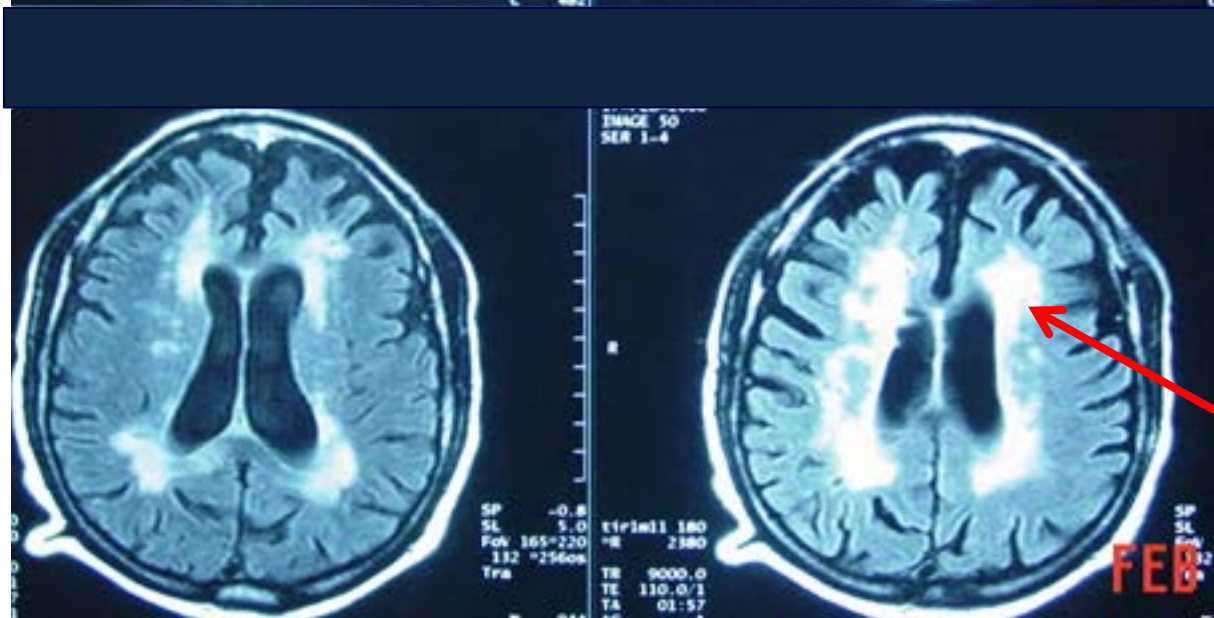Old lacunar  
infarcts in pons  
and thalamus







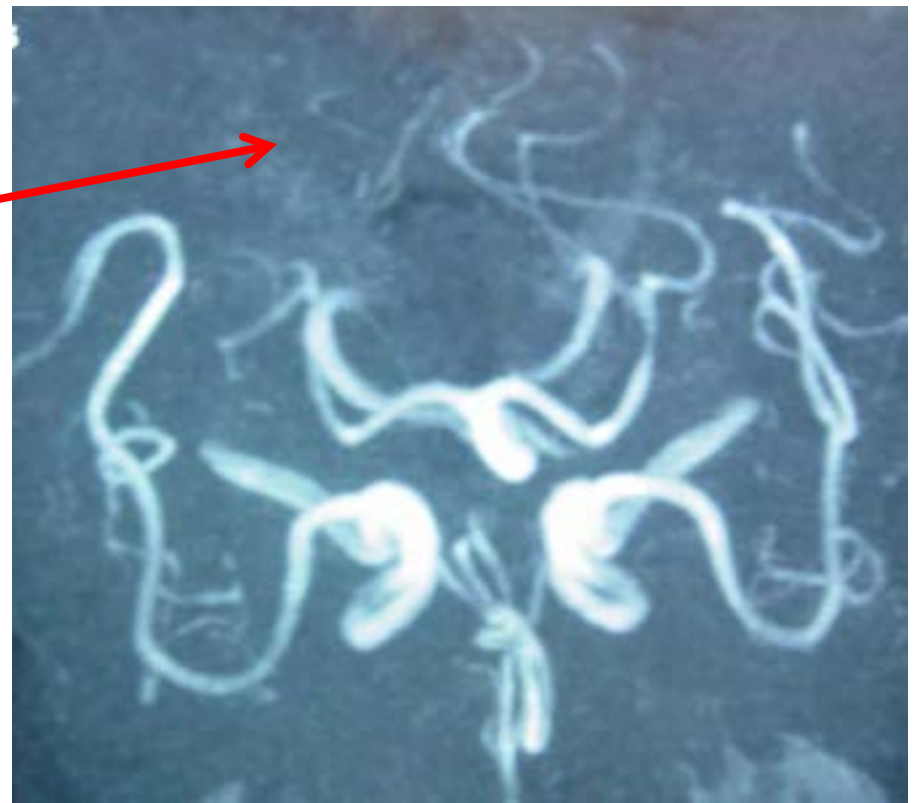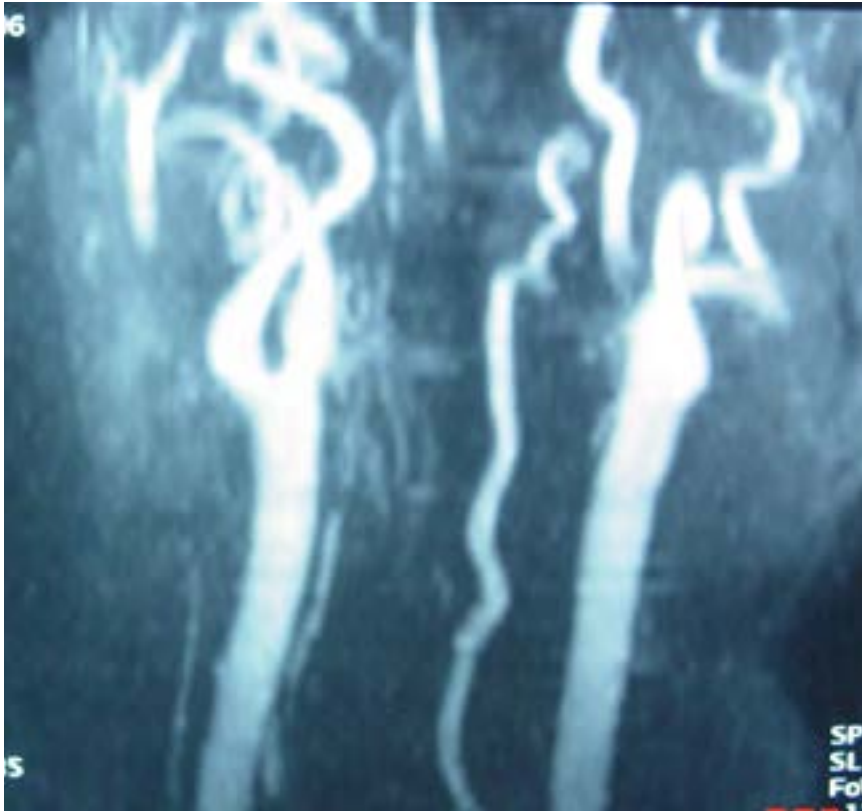
New right  
occipital lobe  
infarct



Hypertensive  
white matter  
changes



MRA: Lack of flow in right PCA



ESR mildly elevated at 39 (age 67);  
CRP normal  
Homocysteine level elevated at 27  
Normal level ( 4.0 – 15.4)

**TREATMENT:**

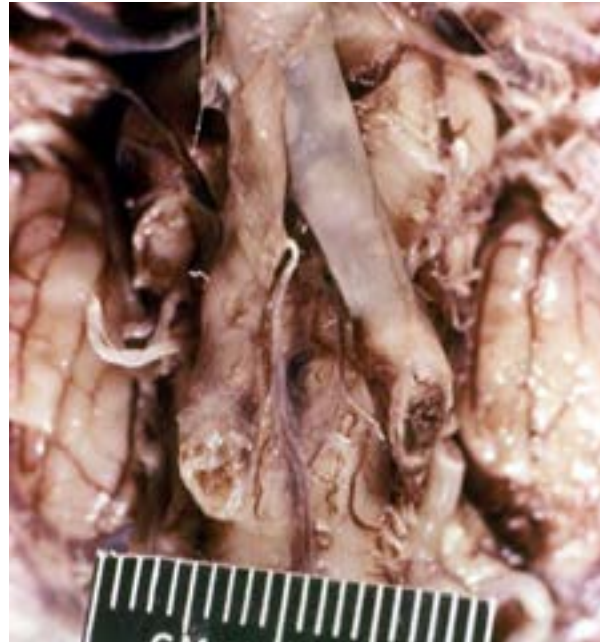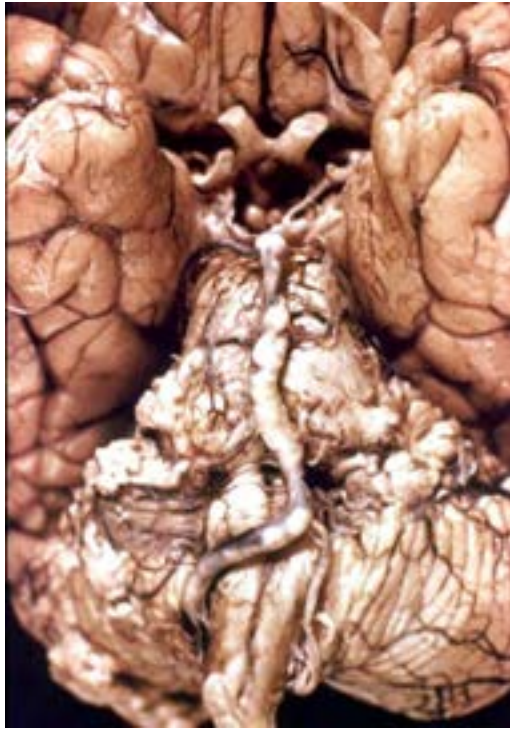Folic Acid  
Re-initiate ASA 81 mg  
Stroke neurology consult



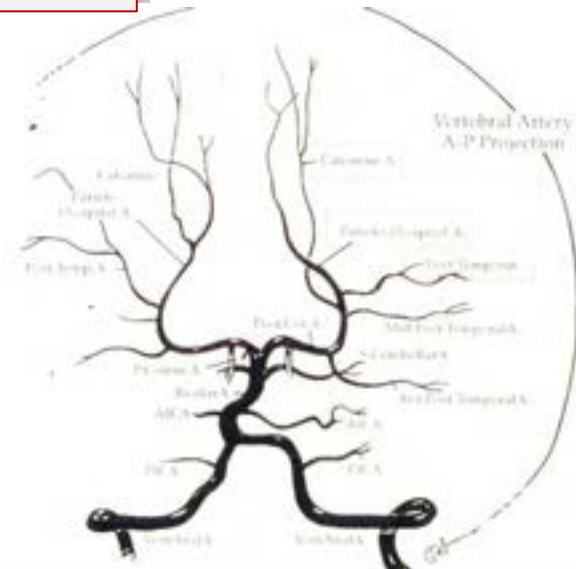
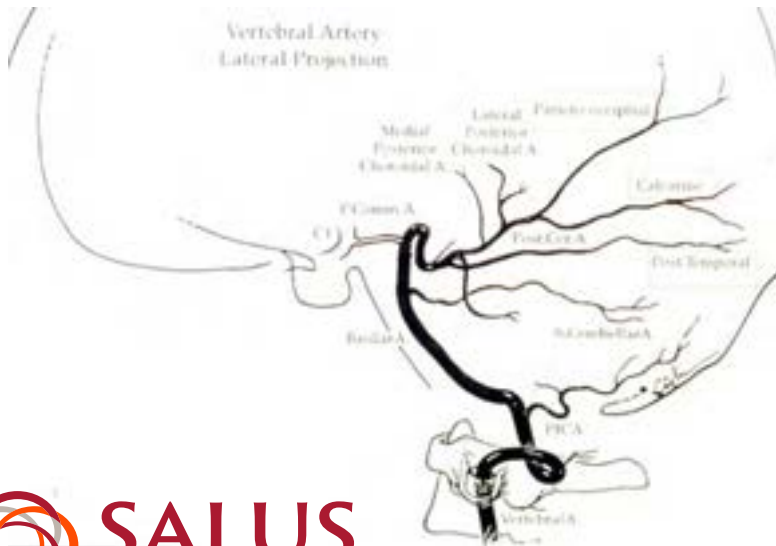
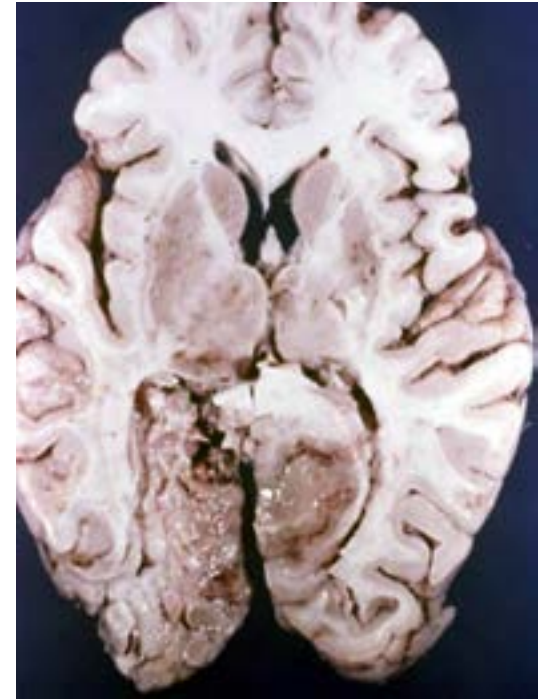
# Occipital Lobe Ischemic Infarct

- POSTERIOR CIRCULATION ABNORMALITY
  - Occlusion of Posterior Cerebral Artery
    - Emboli in PCA
    - Emboli from distant site
      - Distant vessels (basilar, vertebrals, even carotid in some cases)
      - Heart
    - Thrombus





## Posterior circulation infarct



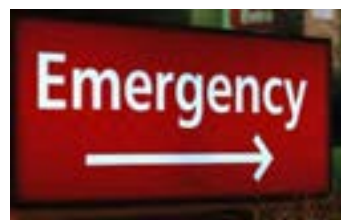

# PANEL DISCUSSION





# ACUTE STROKE = MEDICAL EMERGENCY!



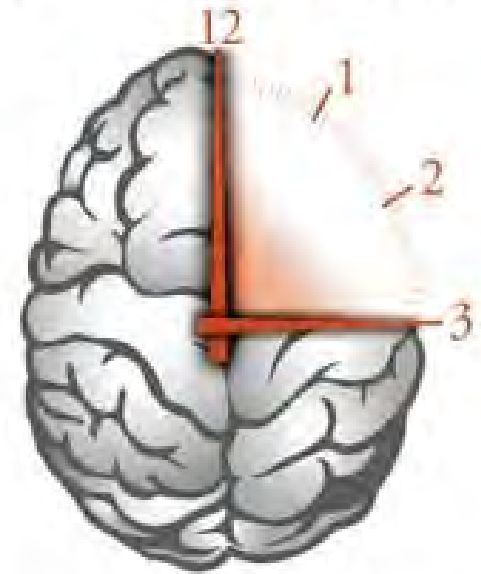
Do not complete eye exam

Only do what you need to confirm  
your stroke suspicion

Call 911 immediately

Tell the dispatcher the patient has  
had an acute stroke

With a stroke...



**time matters.**

**Time is Brain!**

(for BOTH ischemic and hemorrhagic stroke)

## Time to brain death based on % normal blood flow

% NORMAL BLOOD FLOW	TIME TO BRAIN DEATH
NO flow	10 minutes
<30% normal flow	1 hour
30-40% normal flow	Hour to several hours
With collateral and residual flow	Up to 6 hours



Published in **Neurology**  
News - July 24, 2019

### Initiating Stroke Tx 15 Minutes Earlier Can Improve Outcomes

Findings seen in patients with acute  
ischemic stroke treated with  
endovascular-reperfusion therapy

HealthDay

# Get The Patient to the RIGHT ER



- If possible - **Advanced Comprehensive Stroke Center**
- This differs from an Advanced PRIMARY Stroke Center





Door to treatment in  $\leq 60$  min<sup>17,18</sup>



**0 min**

Suspected stroke  
patient arrives  
at ED



**$\leq 10$  min**

Initiate MD evaluation,  
including patient history  
and time last known  
well/symptom onset  
Initiate labwork  
Assess using NIHSS



**$\leq 15$  min**

Notify stroke team  
(including neurologic  
expertise)



**$\leq 25$  min**

Initiate CT scan



**$\leq 45$  min**

Interpret CT scan and labs  
Review patient eligibility  
for Activase



**$\leq 60$  min**

Give Activase bolus  
and initiate infusion  
in eligible patients\*

# rt-PA (thrombolysis)

National Institute of Neurologic Disorders and Stroke (NINDS)

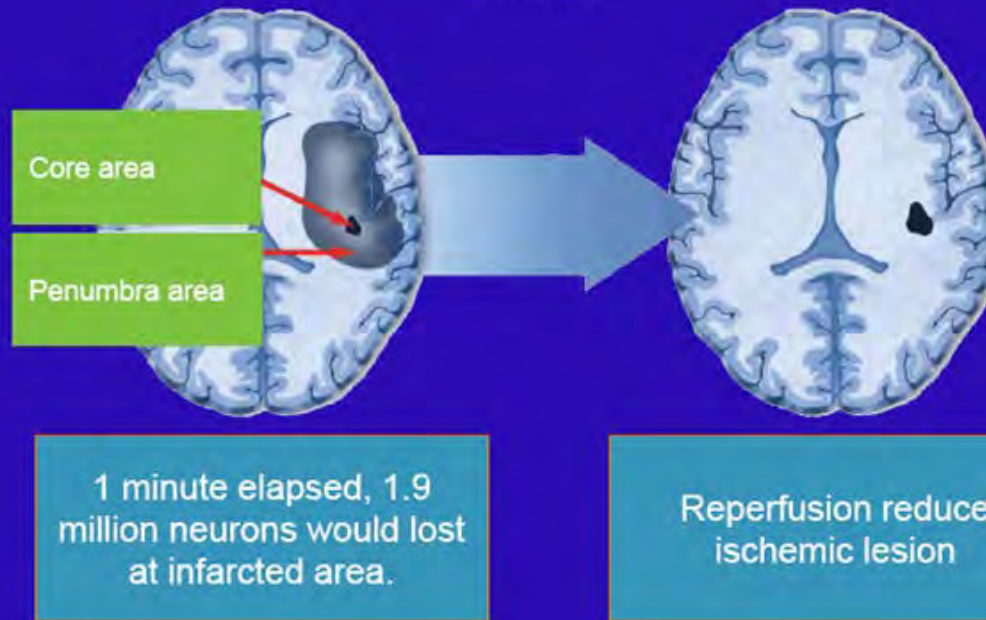
1992: Recombinant tissue type plasminogen activator (rt-PA) study group. FDA approval in 1996.

Early administration of t-PA benefited pts with acute ischemic stroke  
(= **MEDICAL EMERGENCY**)

Initially benefit of t-PA thought to occur in 3 hour window from onset of stroke symptoms. Window was later extended to 4.5 hours (8 fold improvement of ischemic stroke outcomes)

Risk of rt-PA: Hemorrhage (5.2%)

## Reperfusion by IV rt-PA thrombolysis: reduce infarction volume



Saver. *Stroke* 2006;37:263-266.  
González. *Am J Neuroradiol* 2006;27:728-735.  
Donnan. *Lancet Neurol* 2002;1:417-425.

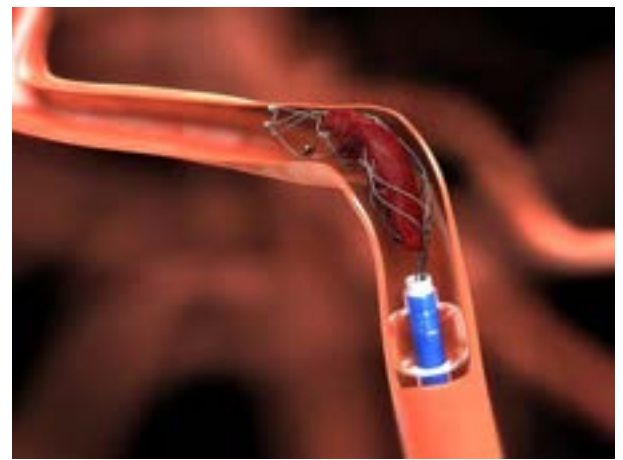
Effective in  $\frac{1}{4}$  to  $\frac{1}{3}$  of patients

If patients are not candidates, the time frame (4.5 hr – sometimes more) has passed, or the treatment was ineffective, there is now another alternative treatment option...

# The Stent Retriever

Used primarily at advanced comprehensive stroke centers

- Tiny wire cage
- Threaded through a catheter into a blood vessel in the groin
- Guided up to the blocked artery in the brain
- Cage opens up and captures the clot
- The stent, along with the clot, is removed
- Immediately blood begins flowing again to the brain



# Transient Ischemic Attack (TIA)

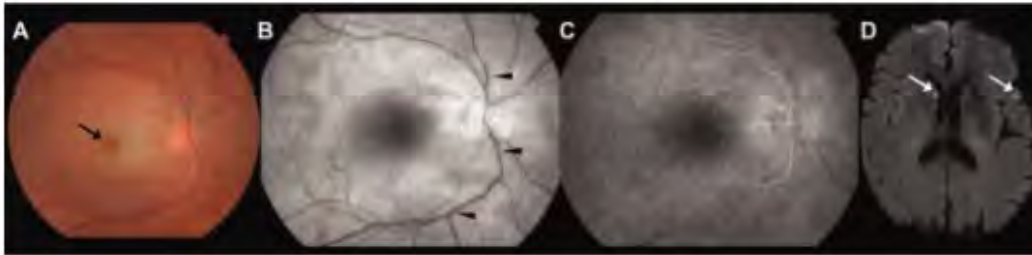
- Neurologic deficit that resolves within 24 hours
- 80% resolve within 1 hour
- 10% of pts with TIA go on to have a stroke in 90 days
- TIA = temporary (includes transient vision loss)
- Stroke = permanent (includes CRAO and BRAO)
- NEED TO BE TREATED THE SAME!!

# Retinal ischemia vs cerebral ischemia

## Concurrent Acute Brain Infarcts in Patients with Monocular Visual Loss

Johanna Helenius, MD,<sup>1</sup> E. Murat Arsava, MD,<sup>1</sup> Joshua N. Goldstein, MD, PhD,<sup>2</sup>  
Dean M. Cestari, MD,<sup>3</sup> Ferdinando S. Buonanno, MD,<sup>4</sup>  
Bruce R. Rosen, MD, PhD,<sup>1</sup> and Hakan Ay, MD<sup>1,4</sup>

ANN NEUROL 2012;72:286–293

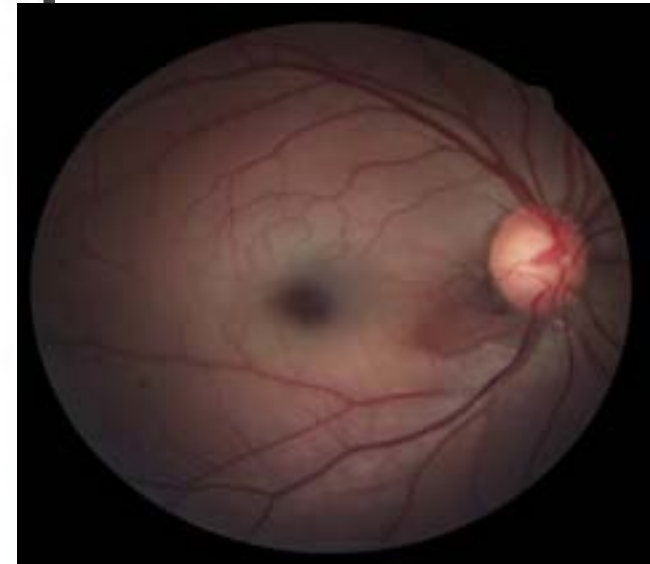

American Journal of Ophthalmology  
June 2014; 157: 1119–1121

EDITORIAL

Acute Retinal Arterial Ischemia: An Emergency Often Ignored

VALÉRIE ROUSSE



- SAME MECHANISMS!
- SAME Guidelines for
  - Stroke
  - TIA
  - CRAO
  - BRAO
  - Transient vision loss

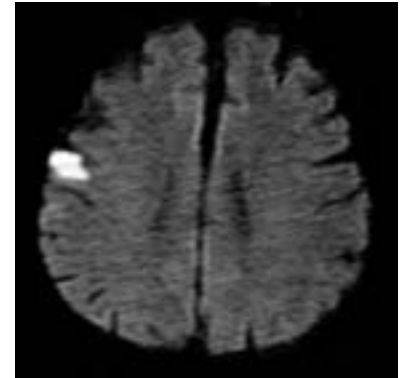


# What's the hurry?

## Co-occurrence of Acute Retinal Artery Occlusion and Acute Ischemic Stroke: Diffusion-Weighted Magnetic Resonance Imaging Study

JUNWON LEE\*, SEUNG WOO KIM\*, SUNG CHUL LEE, OH WOONG KWON, YOUNG DAE KIM, AND SUK HO BYEON

Am J Ophthalmol 2014; 157: 1231-1238



¼ of patients with acute retinal ischemia (even if transient) had an acute brain infarction on brain DWI-MRI

10-15% of patients will have a disabling stroke within 3 months after a TIA, with **half occurring within 48 hours after resolution of TIA.**

## AHA/ASA Guideline

### Guidelines for the Prevention of Stroke in Patients With Stroke and Transient Ischemic Attack

A Guideline for Healthcare Professionals From the American Heart Association/American Stroke Association

Any patient with **suspected TIA or those with acute retinal ischemia** should be evaluated urgently in order to identify those at high risk of immediate cerebral infarction and cardiac ischemia.

Do NOT send these patients to their PCP, cardiologist, neurologist, neuro-ophthalmologist, or retinal specialist.

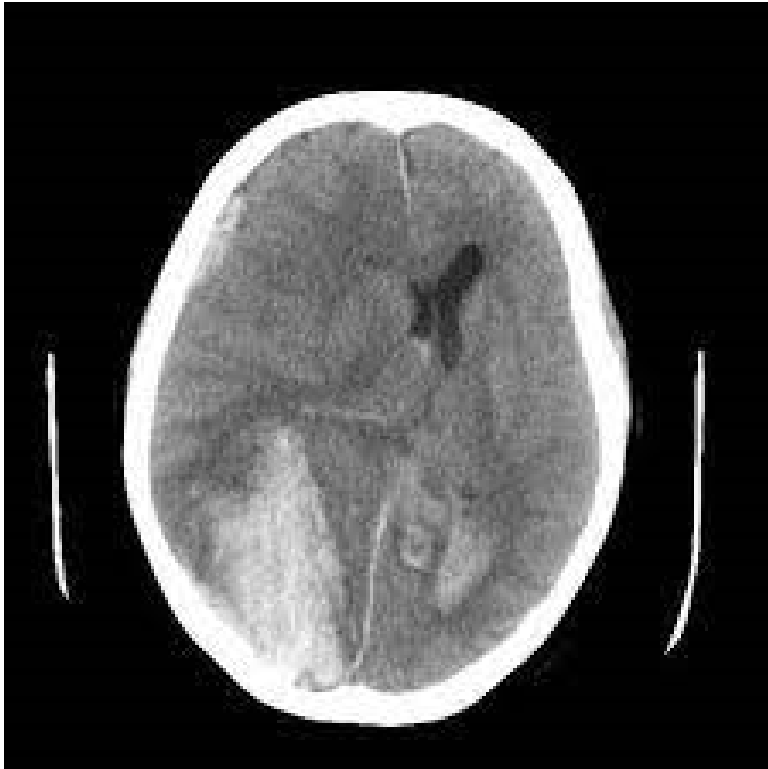Do NOT try to obtain the work-up yourself.

Send to an ED with an Acute Stroke Care Center!





# CT Necessary First to R/O Hemorrhagic Stroke

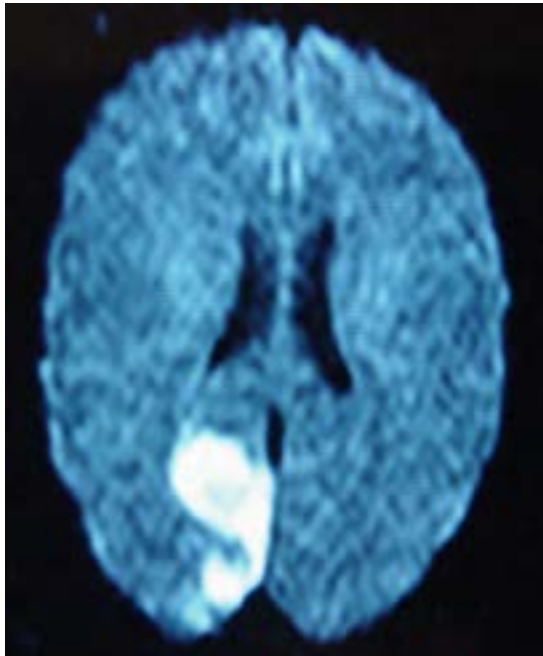


If no hemorrhagic stroke seen, then MRI is necessary, but with certain sequences that are best at detecting acute infarcts



# MRI - Diffusion Weighted Imaging (DWI)

- Very fast recovery time (few msec)
- Used to diagnose ACUTE INFARCTS



- Bright area = acute stroke
- Be aware of normal areas of artifact
- Sensitive to recent changes in vascular perfusion



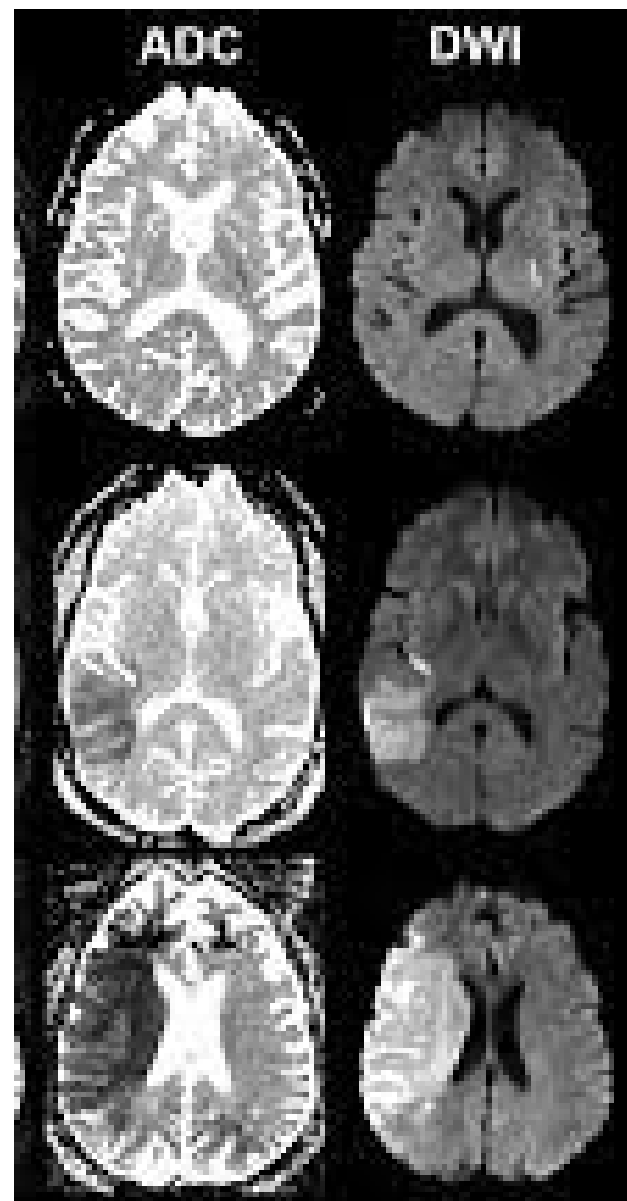
# ADC Map

## Apparent Diffusion Coefficient

- Apparent Diffusion Coefficient has become an important diagnostic aid to DWI.
- ADC is the post processing of DWI.
- ADC maps are usually looked at with more credibility than DW images because there could be T2 shine-through on the DW images. T2 shine-through means the fluid that would normally be bright on a T2 weighted image could appear bright on a DWI since the DWI is usually T2 weighted.



	Restricted Diffusion of molecules	Normal Diffusion of molecules
DWI	Bright	Dark
ADC	Dark	Bright



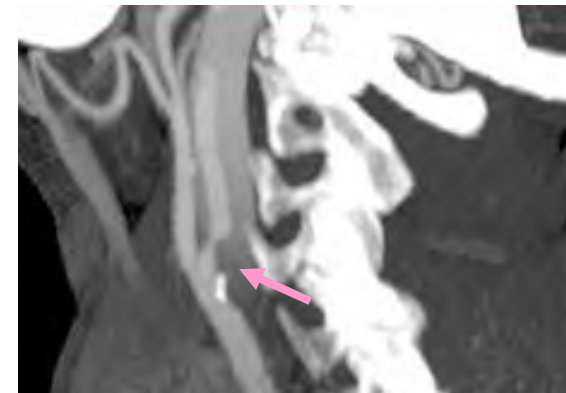
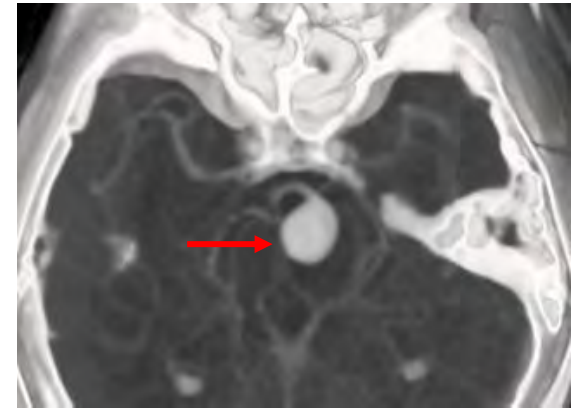
<http://www.ajnr.org/content/40/6/938/tab-figures-data>



# CT Angiography (CTA)

Contrast IS necessary

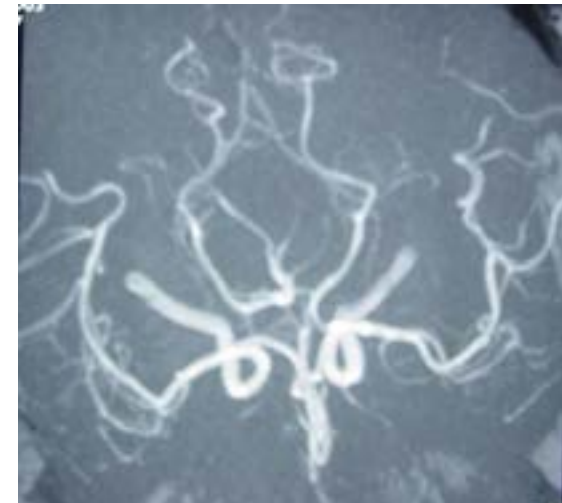
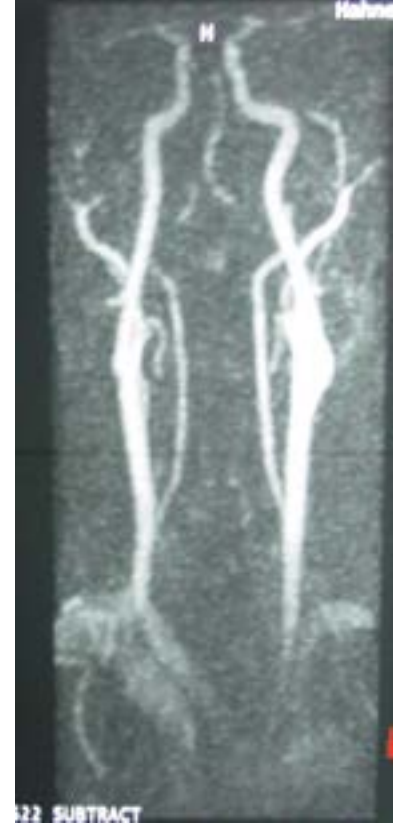- View arteries of head (COW) and neck (carotids, vertebrals)
- Can view as cross-section or in 3D
- Look for aneurysms, AVMs, stenosis





# MRA (head / neck)

- **Contrast NOT necessary**
- View arteries of head (COW) and neck (carotids, vertebrals)
- Image is obtained by flow voids in vessels
- Vessels are normally dark due to movement of blood
- Series of acquisition images are used
- Look for aneurysms, AVMs, stenosis





# Kathy Discussion regarding stroke rehab (some suggestions)

- Time for possible recovery (up to one year)
- Rehabilitation considerations
  - Use of prism for complete homonymous hemianopsias
  - Use of prisms for CN palsies, INO, skew deviation, etc



# Ocular Manifestations of Stroke / TIA (even if transient)

- Anterior Circulation
  - Amaurosis Fugax
  - CRAO / BRAO
  - Ocular Ischemic Syndrome
  - Carotid Artery Dissection
  - Visual Field Neglect
  - Supranuclear Gaze Palsy
- Posterior Circulation
  - Brainstem Motility Disorders
    - INO
    - Skew Deviation
    - Dorsal Midbrain Syndrome
  - Homonymous Hemianopia
  - Disorders of Visual Association Cortex
  - Nystagmus





# HOMONYMOUS HEMIANOPIA

## Prognosis

(Messing B, Ganshirt Neuro-oph 1987)

- Can improve as edema resolves
  - 84% have some amount of recovery at 6 months
  - Allow 1 year to get to maximum recovery
    - » Usually not enough recovery to regain driving ability in those not meeting visual driving requirements right after stroke

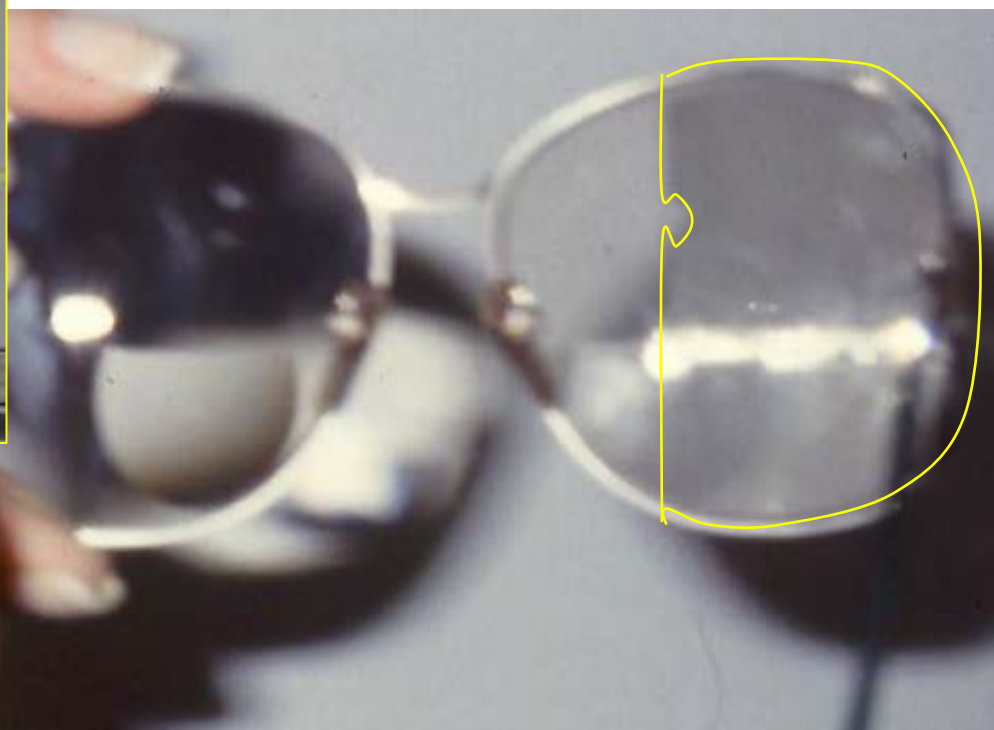
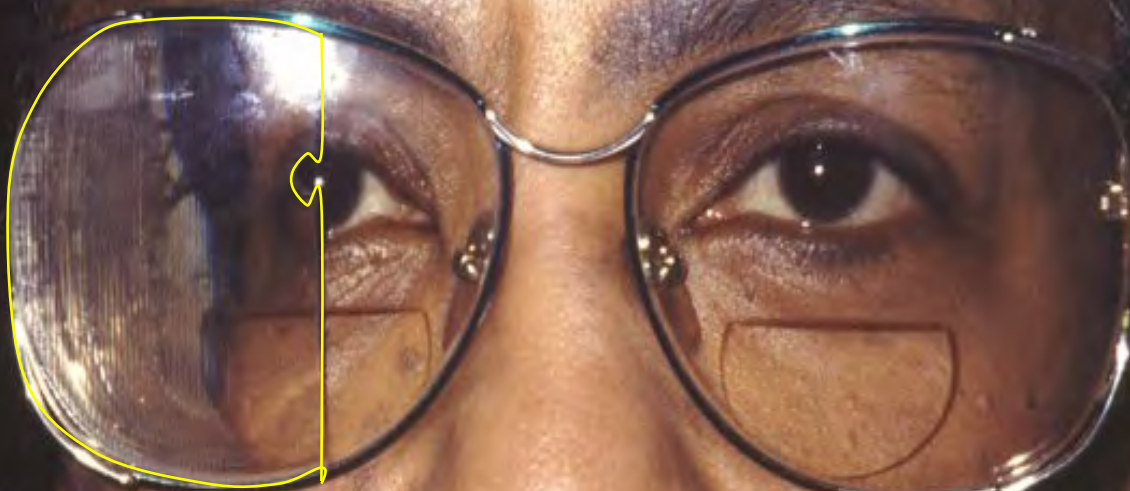
24-3 or 30-2 HVF are NOT good enough to assess driving ability. Need to do Binocular Esterman VF or Goldmann VF.



# HOMONYMOUS HEMIANOPIA VISUAL REHABILITATION

- 30-40 PD FRESNEL PRISM
- BASE OUT to HEMIANOPIC DEFECT
  - SPLIT FIXATION
- BEST CANDIDATES ARE ISOLATED & COMPLETE LEFT HOMONYMOUS
  - 2 WEEK TRIAL

B  
A  
S  
E  
O  
U  
T





# Neurdegenerative Disease Background Information





# NEURODEGENERATIVE DISEASE

- A group of conditions that affect neurons in the brain
- Since neurons can not normally regenerate or reproduce themselves, when they become damaged, it is irreversible
- Neurodegenerative diseases are both incurable and debilitating

- Alzheimer's Disease

- Parkinson's Disease

- Progressive Supranuclear Palsy (PSP)

- Multisystem Atrophy (MSA)

- Amyotrophic Lateral Sclerosis (ALS)

- Multiple Sclerosis (MS)

- Neuromyelitis Optica (NMO)

- Huntington's Disease

- Prion Disease

- Spinocerebellar Ataxia (SCA)

...and more



# Alzheimer's Disease

---

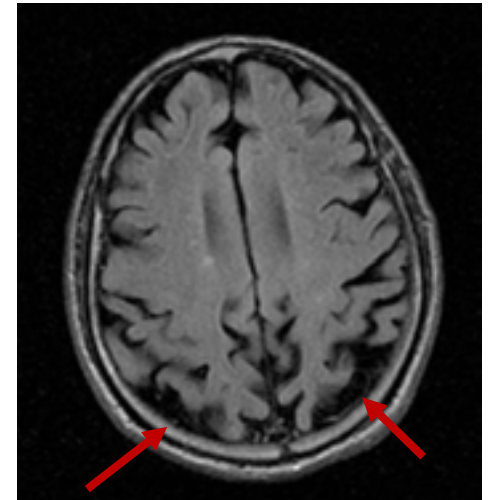
- Progressive neurodegenerative disease
- **Predominantly a disorder affecting memory**
- As the disease progresses, can affect
  - Orientation
  - Attention
  - Language
  - Executive function
  - Visuospatial



# Posterior Cortical Atrophy (PCA)

---

- Neurodegenerative disorder most **commonly associated with Alzheimer disease** pathology
- Characterized by complaints of progressive visual changes
  - Can have a homonymous hemianopia
- A delay in diagnosis of PCA is common
- Search for ocular causes for visual complaints; brain MRI may be interpreted as normal



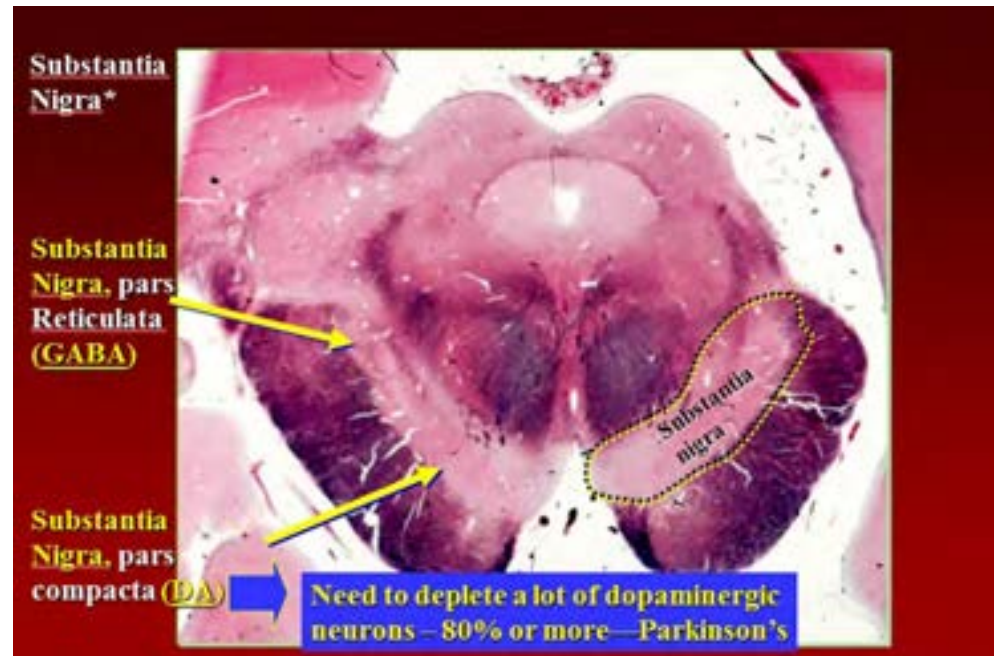
<https://radiopaedia.org/images/4634739>





# Parkinson's Disease

- Considered the 2<sup>nd</sup> most common neurodegenerative disorder
- The mean age of onset is 60 years
- Caucasians are more affected than African and Asian Americans
- Higher rates of occurrence in the Midwest/Great Lakes region and the northeastern USA



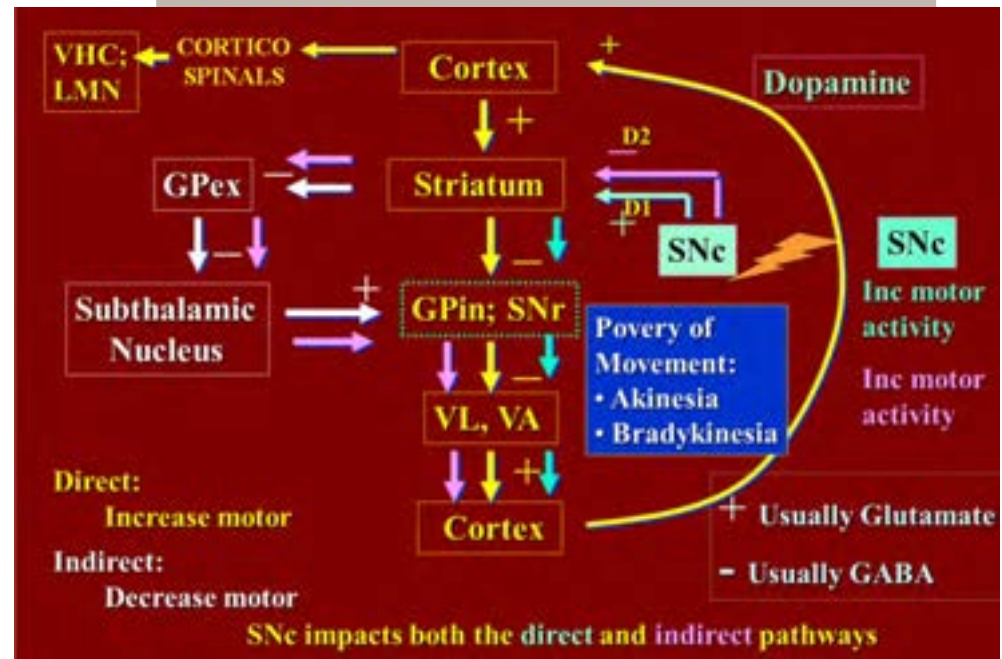




# Parkinson's Disease

## Pathophysiology

- Substantia nigra pars compacta
  - Normally facilitates an increase in motor activity
    - Facilitates the direct pathway
    - Inhibits the indirect pathway
- Dysfunction of the substantia nigra causes a decrease in motor activity
- When approximately 60-80% of the dopaminergic neurons are affected symptoms of Parkinson's begin





# Parkinson's Disease

## Manifestation

- Dyskinesia
    - Bradykinesia
    - Akinesia
    - Resting tremor
  - Dystonia
  - Postural Instability
- Flattened facial expression
  - Hypophonia
  - Micrographia
  - Dream re-enactment
  - Autonomic Nervous System
  - Fluctuation in Attention
  - Dementia

### CLINICAL CHARACTERISTICS OF AD vs PD

<i>Alzheimer Disease (AD)</i>	<i>Parkinson Disease (PD)</i>
Progressive memory impairment	Bradykinesia (slowness of movement)
Impaired executive function (decision making and multi-tasking)	Rigidity and/or Resting Tremor
Behavioral changes (irritability and disengagement)	Postural Instability (later in disease)
Circadian rhythm sleep disturbances	Responds to dopaminergic therapy
Olfactory dysfunction	Olfactory dysfunction



# WHAT IS PARKINSONISM?

- Autonomic dysfunction
- Tremors
- Slow movement (bradykinesia)
- Muscle rigidity
- Postural instability

**Parkinson's Disease is the most common cause of parkinsonism.**

**DISTINGUISHING SYSTEMIC FEATURES OF ATYPICAL PARKINSONIAN SYNDROMES**

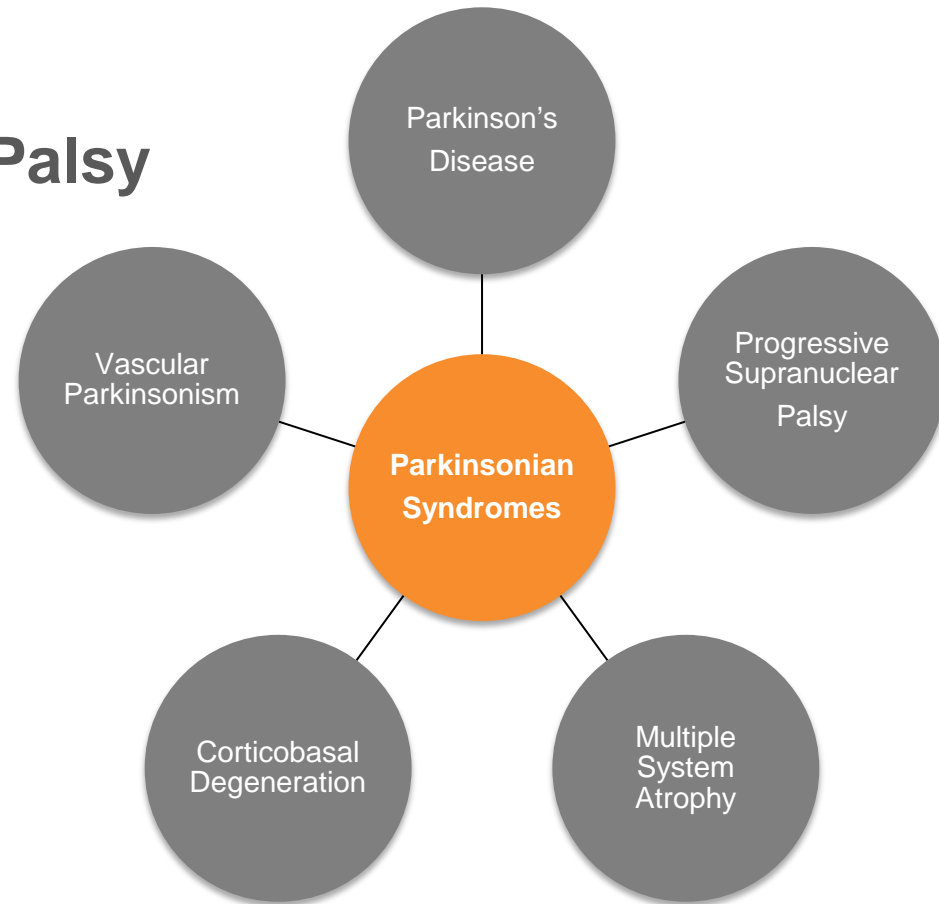
<b>LBD</b> <i>(Lewy Body Dementia)</i>	<b>MSA</b> <i>(Multiple System Atrophy)</i>		<b>PSP</b> <i>(Progressive Supranuclear Palsy)</i>	<b>CBD</b> <i>(Corticobasal Degeneration)</i>
Dementia with visual hallucinations early in disease	Autonomic dysfunction early <ul style="list-style-type: none"> <li>- Orthostatic hypotension (falls)</li> <li>- Loss of bladder control</li> </ul>		Impaired vertical gazes	Asymmetric limb involvement early in disease
Fluctuating cognition	Cognitive function well preserved		Postural instability: prone to backwards falls	Impaired cognition early
REM sleep behavior disorder	Rapid progression (shorter life-span)		Mild executive dysfunction	Profound rigidity
	<b>MSA – P Subtype</b> <i>(predominant Parkinsonism)</i>	<b>MSA – C Subtype</b> <i>(predominant cerebellar ataxia)</i>	Facial dystonia	Dysarthria
	Motor dysfunction similar to PD	Gait and limb ataxia Dysarthria Gaze-evoked nystagmus Ocular dysmetria	Micrographia	Impaired pursuits and saccades
				Ideomotor apraxia (inability to imitate gestures)





# Parkinsonian Syndromes

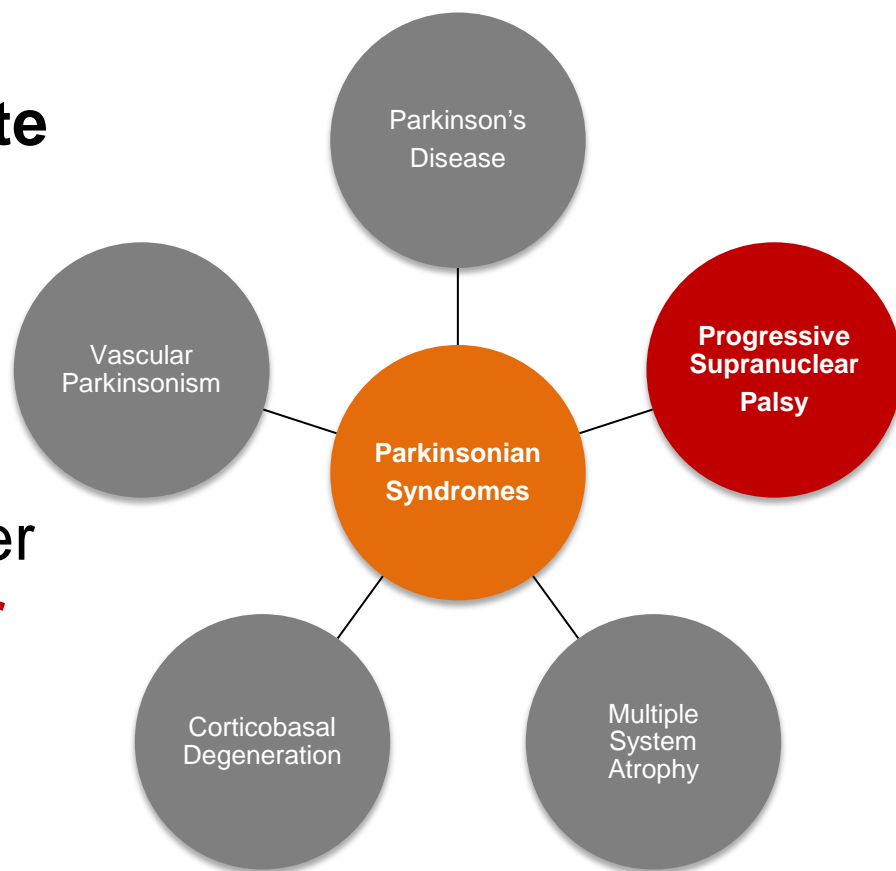
- **Parkinson's Disease**
- **Progressive Supranuclear Palsy**
- **Multiple System Atrophy**
- **Corticobasal Degeneration**
- **Vascular Parkinsonism**





# How To Differentiate From Parkinson's Disease

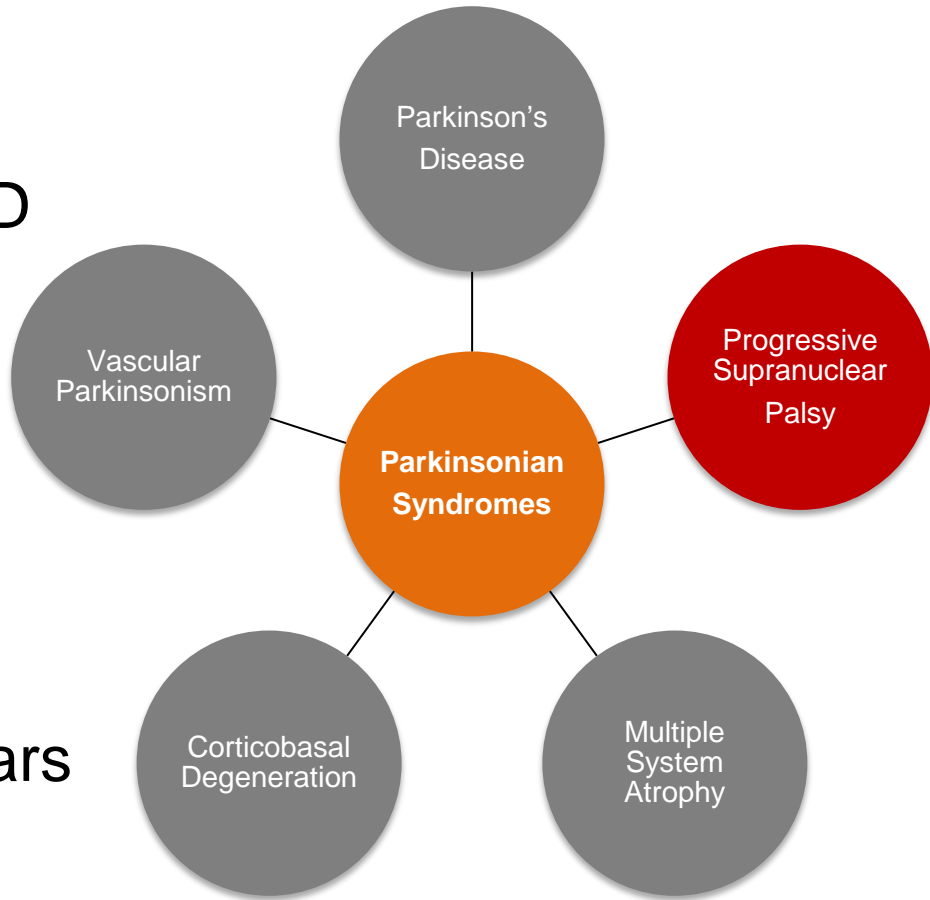
- PD should not demonstrate limited vertical ductions
- If limited vertical eye movements (particularly downgaze), need to consider **Progressive Supranuclear Palsy (PSP)**





# Progressive Supranuclear Palsy (PSP)

- More severe and faster progression compared with PD
- Responds poorly to L-dopa
- Early falls (often backwards)
- Average time to death is 7 years





# NEURODEGENERATIVE DISEASES: THE PURPOSE OF CLINICAL DIAGNOSIS

- Diagnosis is entirely clinical
  - No imaging, biochemical or genetic tests give definite dx
- Diagnosis relies on medical history
  - Timeline of symptoms
  - Important, differentiating clinical signs
  - Differentials
- Although it may not change treatment, it is important to inform the patients, caregivers, family and multidisciplinary care team about the prognosis and progression



# CASE 4

## Neurdegenerative Disease



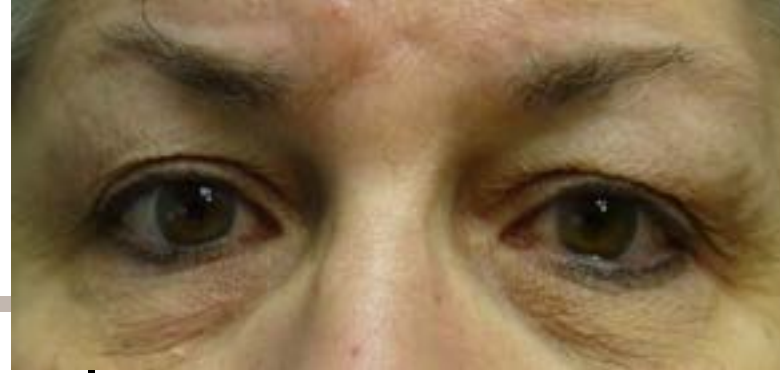



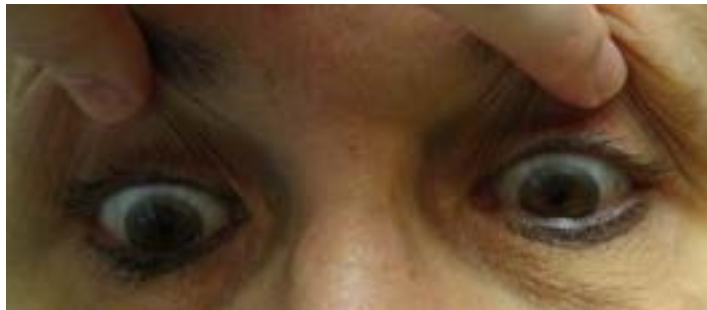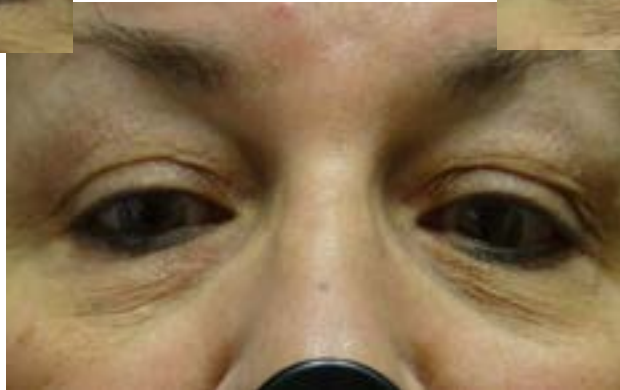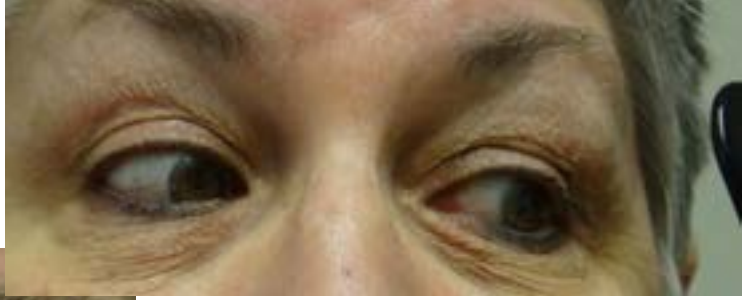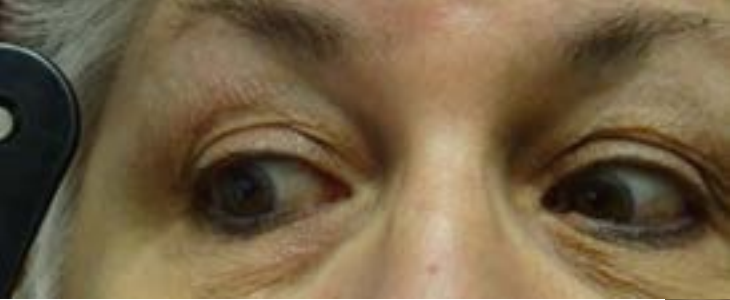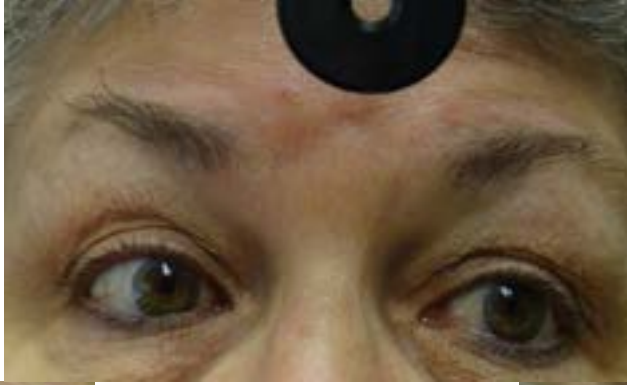# 66 Year-Old Woman

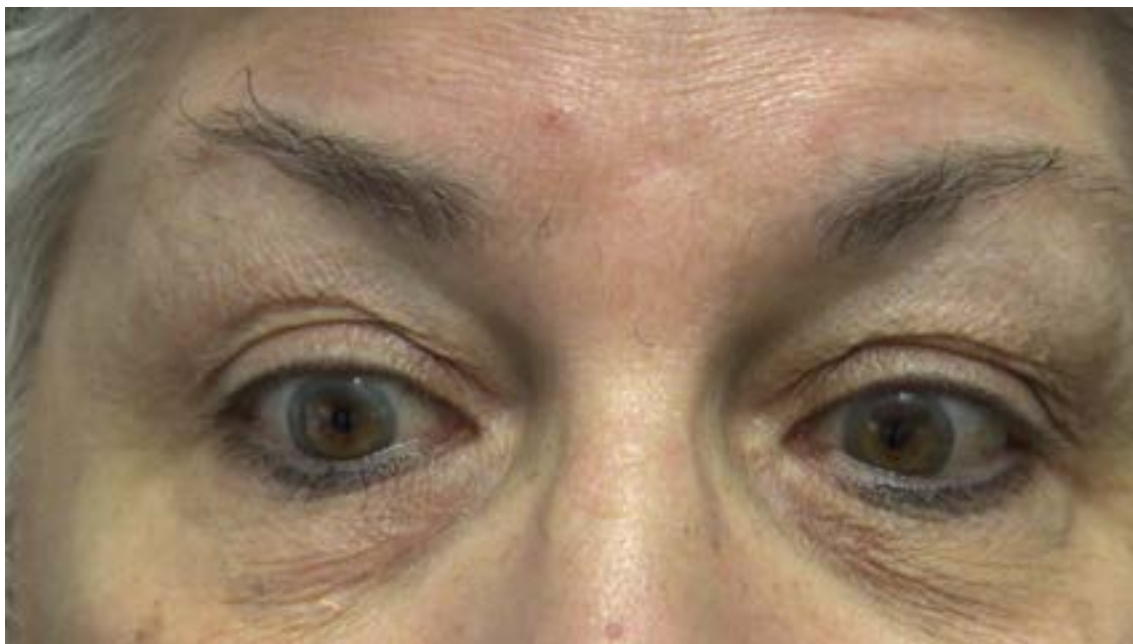---

- Referred by neurology due to abnormal EOMs
- Has been having trouble walking, but she attributes it to arthritis of her knees
- When she gets up, she has to wait for a while before moving
- She holds onto her husband when she walks



- Currently wearing progressive lenses
- Having some difficulty with prolonged reading
- She would like to spend more time reading
- Denies diplopia
- Not currently driving; her husband is not comfortable with letting her drive until they figure out what is going on
- She wants to get back to driving







# Doll's Head (Oculocephalic) Reflex

■ Add video...

A dissociation between impaired voluntary eye movements (pursuits and saccades) and preserved involuntary eye movements (VOR) is called a supranuclear gaze palsy. This is most commonly seen in PSP.

The Doll's head maneuver assesses the vestibulo-ocular reflex (VOR). It can be helpful to distinguish limited ductions as either supranuclear or infranuclear in origin.

The fact that the ability to move the eyes up and down is greater with the Doll's Head maneuver than just with ductions confirms that it is a **supranuclear problem**. Therefore, we know it is not a problem with the nerves, NMJ, or muscles.



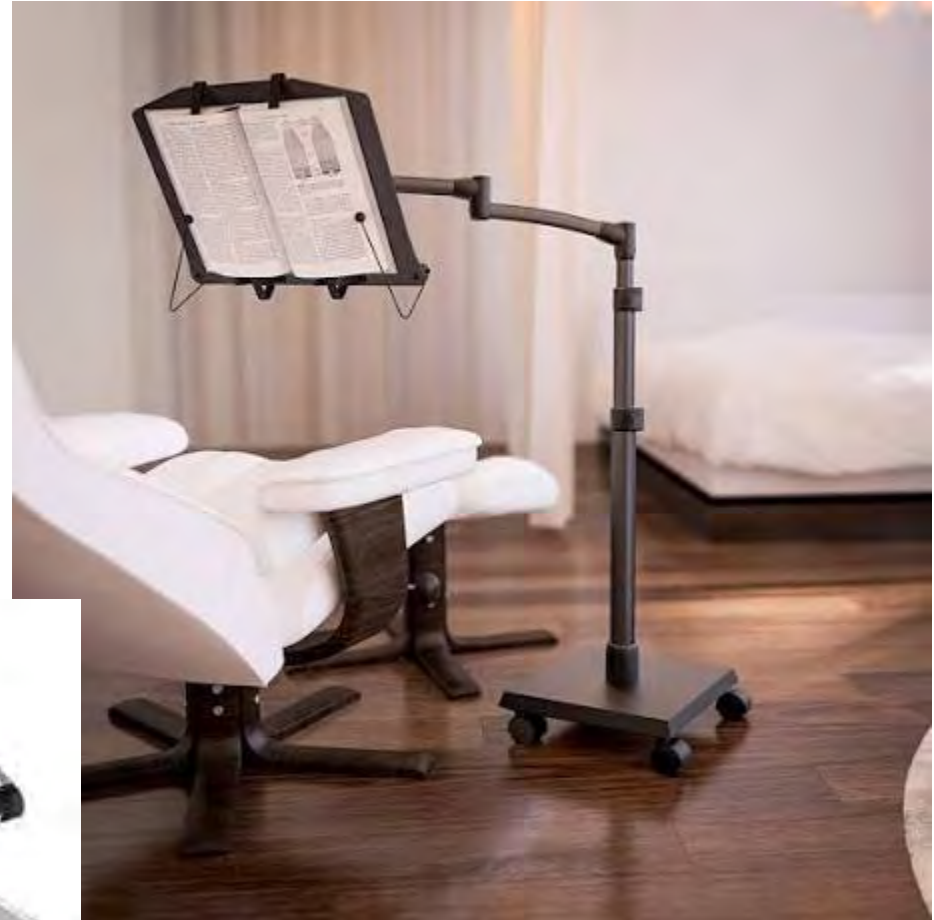# What Can We Do To Help?

---

- Since her vertical motilities are limited (superior > inferior) we need to get her out of progressive lenses
  - They are constantly making her try to make vertical eye movements
- She will do better with separate DVO and NVO lenses
- Incorporated yoked prism since she cannot move her eyes up at all.
  - Want to move image down slightly so it is move comfortable for her
  - 3 BU prism OU (3 BU in each eye)



- Also, recommended a reading stand so that her reading material can be held at eye level







# PANEL DISCUSSION







# Visual Symptoms Are Very Common in Neurodegenerative Diseases!





# Visual and Ocular Manifestations of Alzheimer's Disease and Their Use as Biomarkers for Diagnosis and Progression

Fatimah Zara Javaid<sup>1</sup>, Jonathan Brenton<sup>1</sup>, Li Guo<sup>1</sup> and Maria F. Cordeiro<sup>1,2\*</sup>

**Visual symptoms  
are very  
common in AD!**

TABLE 2 | Visual manifestations of AD.

Indicator of vision	Manifestation of AD	Recommended clinical test*
Visual acuity	Decreased visual acuity in low luminance (32, 33)	HOTV chart
Contrast sensitivity	Reduced visual contrast sensitivity particularly in low frequencies (37, 38) Reduced reading speed at lower contrast sensitivities (37)	Pelli-Robson chart (35) Michelson contrast test (37)
Color vision	Poor color discrimination (43) Deficiencies most significant in tritan axis (31, 42)	City University test Ishihara test (154)
Visual field loss	Inferior hemifield loss (45)	Humphrey automated perimetry (45) FDT (46)
Motion perception	Higher thresholds for motion detection across all spatial frequencies (57)	Computer animation sequences using random dot cinematogram (57)
Depth perception and stereopsis	Reduced stereopsis, mean threshold >150 s of arc	Randot stereotest (155)
Ocular motor function	Abnormal hypometric saccades Increased latency as compared to controls (50, 51)	Eye movement examination (62)

\*All clinical tests require patient cooperation, which can be difficult in AD patients.  
AD, Alzheimer's disease; FDT, frequency doubling technique.



## Research Article

# Visual Symptoms in Parkinson's Disease

R. A. Armstrong

**Visual symptoms are very common in PD!**

- Approximately 80% of patients report at least 1 visual symptom.
- The earlier symptoms are addressed and treated, the better quality of life of the PD patient

TABLE 1: Visual signs and symptoms of Parkinson's disease (PD).

Ocular aspect	Change in PD
Visual acuity	Poor, especially at low contrast
Colour vision	Vision blurred for coloured stimuli Shortened colour fusion time Progressive deterioration
Visual fields	Increase in glaucomatous visual field defects Side effects of surgery
Saccadic eye movement	Reaction time and max. velocity of horizontal gaze slower Hypometria Amplitude increased after cued saccades Affected early in disease process
Smooth pursuit movement	Superimposed saccades Reduction in response magnitude
Optokinetic Nystagmus	Abnormal in some patients
Convergence	Impaired, associated with large exophoria, diplopia
Blink frequency	Reduced, causing abnormal tear film, dry eye and reduced vision
Blink reflex	Habituation not observed
Pupil diameter	Larger after light adaptation with anisocoria
Light reflex	Longer latency
Constriction time	Increased
Contraction amplitude	Reduced
Contrast sensitivity (CS)	Abnormal in some cases, intermediate to high frequencies
Temporal processing	Impaired ability to track rapid fluctuations Duration perception affected
Flash ERG	Reduced amplitude of "b" wave Reduced amplitudes.
PERG	Specific defect at medium SF Delayed P50
Cortical VEP	Delayed P100
Chromatic VEP	Increased latency and reduced Amplitude (esp. blue-yellow)
ERP	Abnormal, Delayed reaction times
Visuo-spatial	Difficulty in judging verticals, position of body parts, and in route-walking tasks
Orientation and motion discrimination	Impaired
Facial perception	Impaired ability to perceive and imagine emotional faces
Visual hallucinations	Chronic in 30–60% of treated cases

Abbreviations: ERG: Electroretinogram, ERP: event-related potentials, PERG: Pattern electroretinogram, SF: Spatial frequency, VEP: Visual evoked potentials



# AD & PD and Afferent Function Symptoms are Similar

---

- Blur
- Difficulty seeing in twilight or in rain
- Colors are washed out
- Vision just is not right
  
- Reduced Visual Acuity
- Reduced Color Discrimination
- Reduced Contrast Sensitivity





# PD and Eye Movements

Basal ganglia are involved in saccadic eye movements

- **Abnormal saccadic and smooth pursuit eye movements in about 75% of PD patients!**

- **SACCADES**

- Reduced maximum velocity and reaction time
- Hypometric (early stages)
- Increased latency (later stages)

- **PURSUIITS**

- Saccadic pursuits
- Jerkiness and “cog-wheeling” of eye movements
  - ◆ Vertical movements more impaired
- Progressive decline of pursuit response with repetition






# PD Associated Dry Eye Syndrome

## ■ VERY COMMON

- Ocular surface irritation
- **Affects up to 60% of PD patients**
- Due to:
  - ◆ Poor tear distribution
  - ◆ Poor tear production
  - ◆ Abnormal tear composition
  - ◆ **Decreased blink rate and amplitude (akinesia / bradykinesia)**
    - Increased blink duration
    - No habituation of blink reflex with tap above bridge of nose
      - ◆ Glabellar reflex (primitive reflex)



**There can be a classic “serpentine stare” appearance in PD due to reduced blink rate**





# Visual Hallucinations in Neurodegenerative Disease

## VISUAL HALLUCINATIONS IN NEURODEGENERATIVE DEMENTIAS

AD

PD

DLB

MSA

CBS

Parkinsonian Syndromes

Possible in  
**late** stage

Possible

Common in  
**early** stage  
(Part of diagnostic criteria)


Uncommon

Uncommon



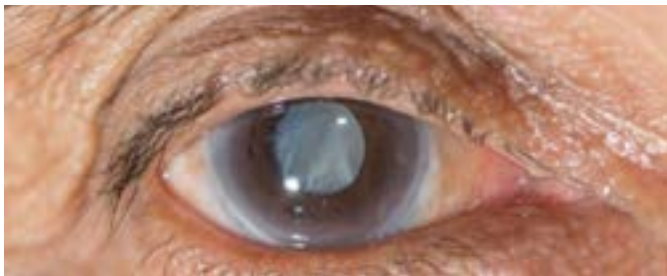


# AD and Hallucinations



Visual hallucinations are a common finding

- Associated with more rapid cognitive decline
- **60% of patients with visual hallucinations, could improve with refraction**
- **Cataracts significantly associated with visual hallucinations**
- Hallucinations were not seen with normal visual acuity



**AD PATIENTS BENEFIT FROM CATARACT SURGERY!**





# PD and Hallucinations

- Occurs more often in the setting of
  - Insomnia (REM sleep disorders)
  - Daytime sleepiness
  - Moderate to severe cognitive issues
  - Longer duration of PD
  - Reduced visual acuity
  - **PD medications (all cause hallucinations, but these more so)**
    - Amantadine
    - Mirapex
    - Neupro
    - Requip



**Visual hallucinations are common in PD!**

**About 50% of PD patients experience hallucinations!**



# VISUAL HALLUCINATIONS

## Hallucinations

- Simple (non-formed)
- Complex (formed)

Formed

People

Animals

Objects

Vivid scenes

Colors



**Parkinsonian hallucinations are usually complex, binocular hallucinations which occur throughout the entire VF**



# PD and Hallucinations

---

## ■ TREATMENT

Reassurance

Change in meds

**If severe, there is now a medication to treat PD hallucinations – Pimavanserin (Nuplazid)**





# DEMENTIA WITH LEWY BODIES



## ■ Visual hallucinations

- Occur in **2/3 of patients with DLB**
- **Early sign in DLB and may precede parkinsonism**
- Often under-reported unless specifically asked about
- Patient reactions to the hallucinations
  - ◆ Fear
  - ◆ Indifference
  - ◆ Enjoyment

**Visual hallucinations are a useful feature to distinguish DLB from AD. Hallucinations occur more often in DLB as compared with AD.**

## ■ Descriptions range:

- well-formed images of people or animals
- abstract visions such as shapes or colors
- visual misperceptions
  - ◆ object seems to move, zoom toward or away from the patient, or change shape.

**Remember, in AD, hallucinations were NOT seen with normal VA.**

## Criteria for Diagnosing Dementia with Lewy Bodies.

### Core clinical features:

- Fluctuating cognition
- Visual hallucinations
- REM sleep behavior disorder
- Parkinsonian features

## Revised criteria for the clinical diagnosis of dementia with Lewy bodies (DLB)

<b>Probable DLB</b>	<ul style="list-style-type: none"> <li>Two or more core clinical features of DLB are present, with or without indicative biomarkers; <b>OR</b></li> <li>Only one core clinical feature is present, but with one or more indicative biomarkers</li> <li>Probable DLB should not be diagnosed on the basis of biomarkers alone</li> </ul>
<b>Possible DLB</b>	<ul style="list-style-type: none"> <li>Only one core clinical feature of DLB is present, with no indicative biomarker evidence; <b>OR</b></li> <li>One or more indicative biomarkers are present, but there are no core clinical features</li> </ul>
<b>DLB is less likely</b>	<ul style="list-style-type: none"> <li>In the presence of any other physical illness or brain disorder including cerebrovascular disease, sufficient to account in part or in total for the clinical picture*</li> <li>If parkinsonian features are the only core clinical feature and appear for the first time at a stage of severe dementia†</li> </ul>
<b>Essential features</b>	<b>Dementia<sup>Δ</sup></b>
<b>Core clinical features</b> (the first three typically occur early and may persist throughout the course)	<ul style="list-style-type: none"> <li>Fluctuating cognition with pronounced variations in attention and alertness</li> <li>Recurrent visual hallucinations that are typically well formed and detailed</li> <li>REM sleep behavior disorder, which may precede cognitive decline</li> <li>One or more spontaneous cardinal features of parkinsonism (bradykinesia, rest tremor, rigidity)</li> </ul>
<b>Supportive clinical features</b>	<ul style="list-style-type: none"> <li>Severe sensitivity to antipsychotic agents</li> <li>Postural instability</li> <li>Repeated falls</li> <li>Syncope or other transient episodes of unresponsiveness</li> <li>Severe autonomic dysfunction (eg, constipation, orthostatic hypotension, urinary incontinence)</li> <li>Hypersomnia</li> <li>Hyposmia</li> <li>Hallucinations in other modalities</li> <li>Systematized delusions</li> <li>Apathy, anxiety, and depression</li> </ul>
<b>Indicative biomarkers</b>	<ul style="list-style-type: none"> <li>Reduced dopamine transporter uptake in basal ganglia by SPECT or PET</li> <li>Abnormal (low uptake) <sup>123</sup>Iodine-MIBG myocardial scintigraphy</li> <li>Polysomnographic confirmation of REM sleep without atonia</li> </ul>
<b>Supportive biomarkers</b>	<ul style="list-style-type: none"> <li>Relative preservation of medial temporal lobe structures on CT/MRI scan</li> <li>Generalized low uptake on SPECT/PET perfusion/metabolism scan with reduced occipital activity &amp; cingulate island sign on FDG-PET imaging</li> <li>Prominent posterior slow-wave activity on EEG with periodic fluctuations in the pre-alpha/theta range</li> </ul>

DLB: dementia with Lewy bodies; REM: rapid eye movement; SPECT: single-photon emission computed tomography; PET: positron emission tomography; MIBG: metaiodobenzylguanidine; CT: computed tomography; MRI: magnetic resonance imaging; FDG: fluorodeoxyglucose; EEG: electroencephalography.

\* These do not exclude a DLB diagnosis and may serve to indicate mixed or multiple pathologies contributing to the clinical presentation.

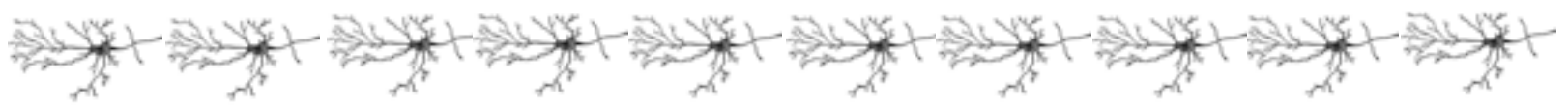† DLB should be diagnosed when dementia occurs before or concurrently with parkinsonism. The term "Parkinson disease dementia" (PDD) should be used to describe dementia that occurs in the context of well-established Parkinson disease. Δ Dementia is defined as a progressive cognitive decline of sufficient magnitude to interfere with normal social or occupational functions, or with usual daily activities. Prominent or persistent memory impairment may not necessarily occur early in the early stages but is usually evident with progression. Deficits on tests of attention, executive function, and visuospatial ability may be especially prominent and occur early.

Modified from: McKeith IG, Boeve BF, Dickson DW, et al. Diagnosis and management of dementia with Lewy bodies: Fourth consensus report of the DLB Consortium. *Neurology* 2017; 89:88. DOI: [10.1212/WNL.0000000000004058](https://doi.org/10.1212/WNL.0000000000004058). Copyright © 2017 American Academy of Neurology. Reproduced with permission from Lippincott Williams & Wilkins. Unauthorized reproduction of this material is prohibited.



Visual hallucinations are under-reported by patients who fear that the hallucinations represent psychiatric disease or who lack insight into the unreal nature of the hallucinations.

We need to ask patients if they are experiencing visual hallucinations.



# Kathy Discussion regarding NDG rehab (some suggestions)

- CI in Parkinson's – BI prism
- Separate DVO and NVO Rx vs PALs
- Use of yoked prism in PSP



# Cognitive Impairments & Dementias

---

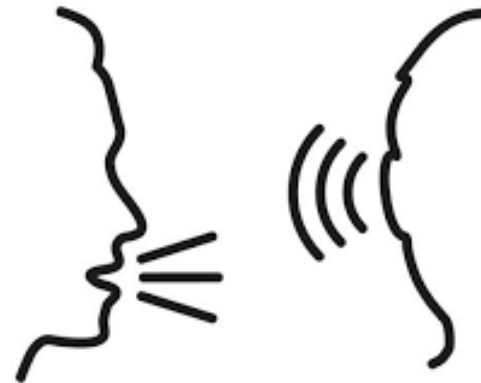
- Since most parts of the brain play some role in visual function, these conditions will have some visual / ocular manifestations.

- **STRUCTURAL**

- ◆ OCT
- ◆ OCT-A
- ◆ OCULAR HEALTH

- **FUNCTIONAL**

- ◆ AFFERENT
- ◆ EFFERENT



Listening to the patient and their caretaker will help you know how you can best help them.





# COGNITIVE IMPAIRMENT & DEMENTIA

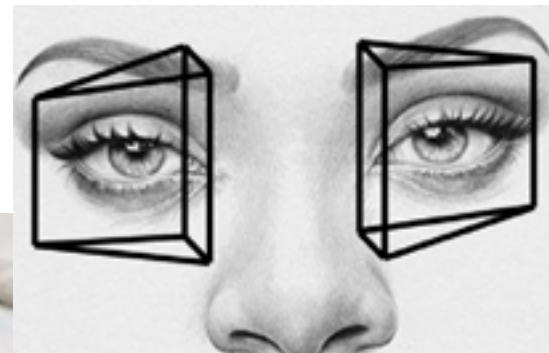
---

- Patients will often have problems with:
  - Reading
  - Driving
  - Performing tasks that depend on visual cognition
  - Diplopia
  - Eye movement abnormalities
  
- Our job is to assess and manage visual cognition and to improve visual function when possible



# PD and Binocular Diplopia from CI

- Separate glasses for distance and near
- BI prisms in reading glasses
- Vision Therapy
- Patching



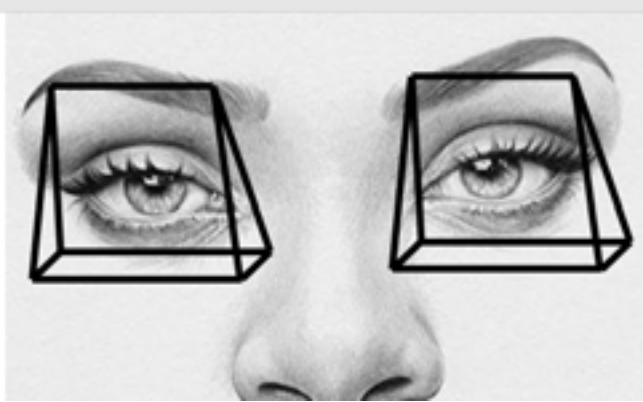
- **Recommend reading stand due to hand tremors**



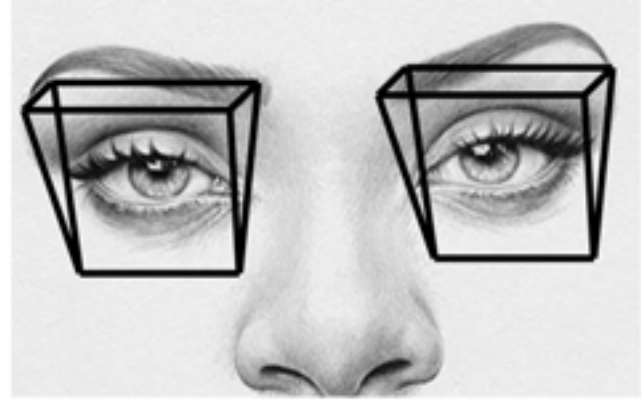


# Yoked Prism in PSP

- Reduced Vergence Ranges



Helps with Reduced  
Infraduction



Helps with Reduced  
Supraduction



# Traditional Neuroimaging is Not Diagnostic in Neurodegenerative Disease

- Imaging is done to rule out other etiologies for the clinical presentation
- There are no reliable imaging biomarkers for AD
- DaT scan may be helpful in PD
- Midbrain atrophy may be seen in PSP





# PSP - diagnosis

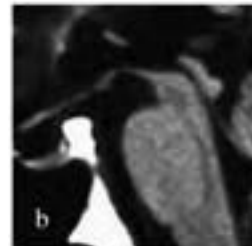
**Characteristic eye movements help confirm the diagnosis of PSP**

- Initially as slowing of vertical saccades
- Gradually evolve into hypometric saccades, square-wave jerks (fixation instability)
- Eventually supranuclear vertical gaze palsy

The radiologic **hummingbird sign** (also called the penguin silhouette sign) results from the prominent midbrain atrophy in PSP with a relatively preserved pons, resembling a hummingbird or penguin in silhouette on midsagittal MRI of the brain.



Remember that the midbrain is the vertical gaze center.



Classic Hummingbird sign of MRI

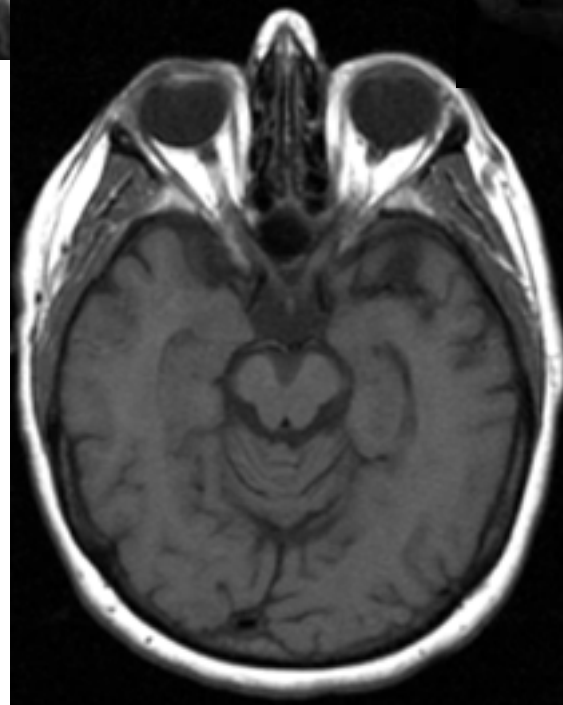
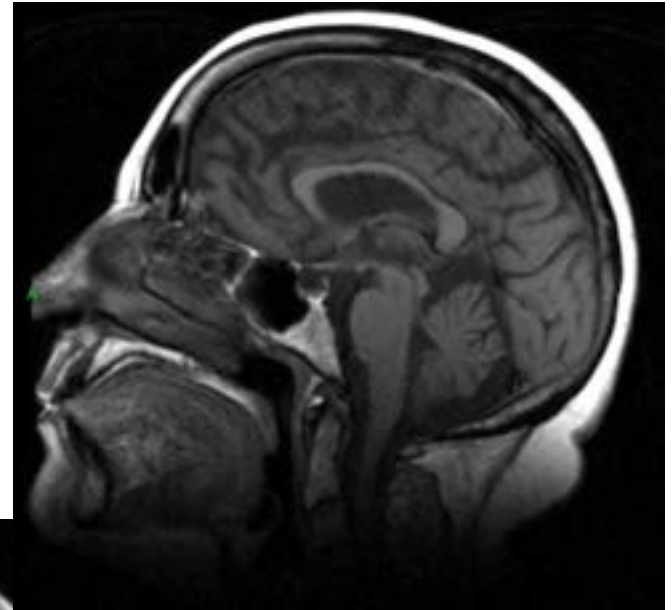
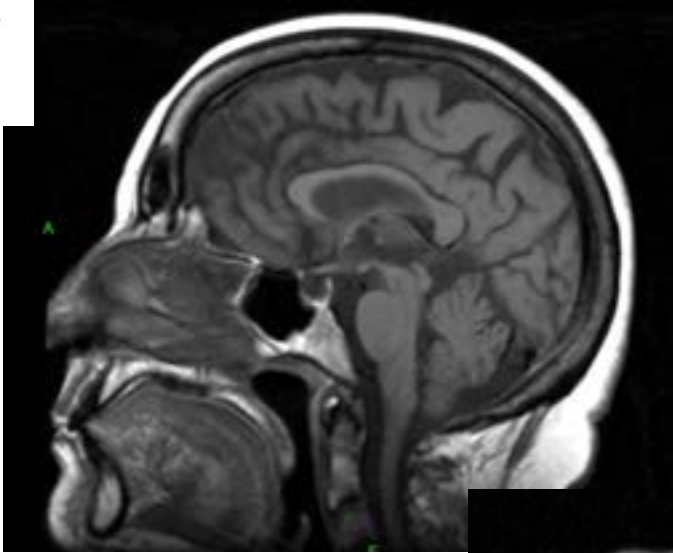
(a) Hummingbird, (b) mid-sagittal plain MRI in PSP. The region including the most rostral midbrain, the midbrain tegmentum, the posterior horn, and the cerebellum appears to correspond to the tail, crown, body, and wing, respectively, of a hummingbird (i.e., the "hummingbird sign"). Adapted from "Kane N, Aziz K, Hassan T. Study of the rostral midbrain atrophy in progressive supranuclear palsy. J Neurol Sci. 2003 Jun;193(1-2):57-60."

From [Progressive Supranuclear Palsy](#)



StaffWorks Internet  
Toucan Island (PL) StaffWorks Publishing 2018 Jan-

Neuropathologic examination remains the gold standard for its definitive diagnosis





# OCT in Neurodegenerative Disease

**The pathological changes of Alzheimer's Disease (AD) occur decades before the onset of dementia**, but AD is typically diagnosed late in the disease course when extensive and irreversible neurodegeneration and vascular damages have already occurred.

There is great interest in discovering new **biomarkers that can identify individuals suffered from earlier stages of AD**, which are more likely to benefit from any effective treatments.

**We will have a role in assessing risk of AD and other forms of dementia by use of OCT.**

The retina is an extension of the brain embryologically, anatomically and physiologically. It is the CNS.

OCT in Alzheimer's has been studied a bit more than OCT in Parkinson's. But, similar concepts apply.



## Spectral Domain-Optical Coherence Tomography Measurements in Alzheimer's Disease: A Systematic Review and Meta-analysis

Victor T.T. Chan<sup>1,2</sup>, Zihan Sun<sup>1</sup>, Shumin Tang<sup>1</sup>, Li Jia Chen<sup>1</sup>, Adrian Wong<sup>2</sup>, Clement C. Tham<sup>1</sup>, Tien Y. Wong<sup>3,4</sup>, Christopher Chen<sup>5,6</sup>, M. Kamran Ikram<sup>7</sup>, Heather E. Whitson<sup>8,9</sup>, Eleonora M. Lad<sup>8</sup>, Vincent Mok<sup>\*,2,10</sup>, and Carol Y. Cheung<sup>\*,1</sup>

**Conclusion:** Our results confirmed the associations between retinal measurements of SD-OCT, and AD, highlighting the potential utility of SD-OCT measurements as biomarkers of AD.

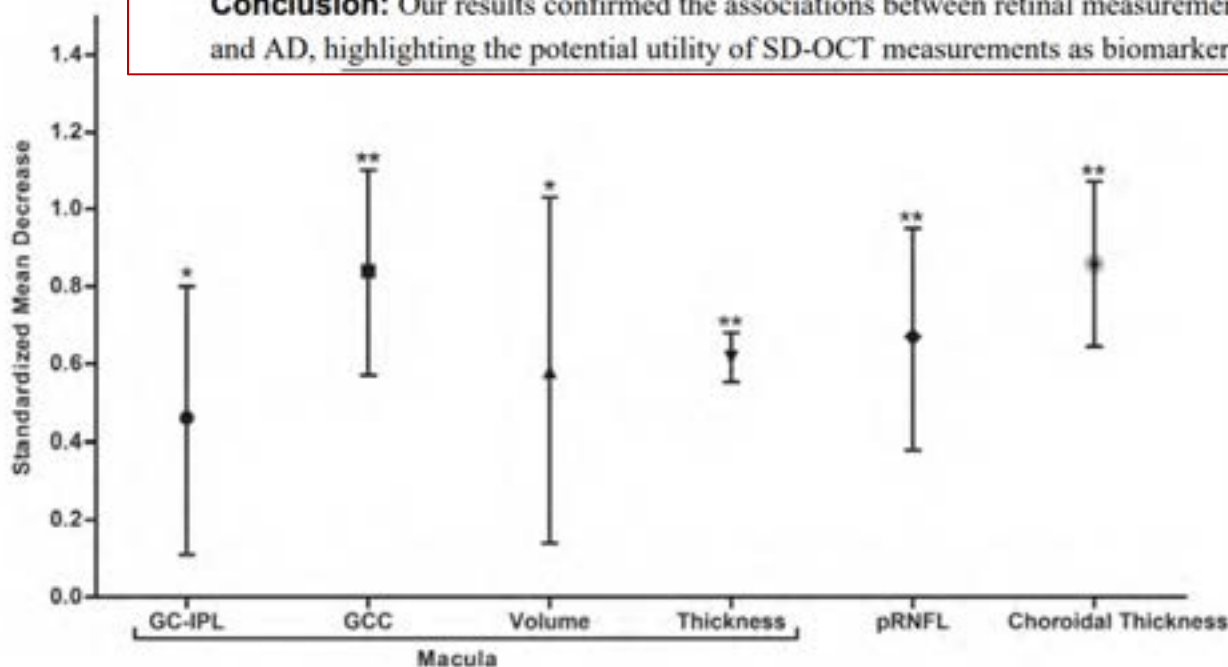


Figure 13: Differences in SD-OCT measurements between subjects with AD and controls. The standardized mean decreases of SD-OCT measurements in AD are shown. The bars represent the 95% confidence intervals of the standardized mean decreases. Significant group differences with  $p < 0.05$  and  $p < 0.001$  are labelled as "\*" and "\*\*" respectively.





## 2 Possible Mechanisms For SD-OCT Findings in AD

- The cerebral pathology of AD may affect the visual pathway and cause **retrograde degeneration** of the optic nerve
  - AD pathologic features can be found in subcortical visual centers
    - lateral geniculate nucleus
    - superior colliculus
  - **RGC neuronal abnormalities were also associated with non-AD dementias**
- Alternatively, it is also possible that **AD pathology occurs simultaneously both in the brain and the retina**, leading to thinning of the retinal neuronal layers.



# Optical Coherence Tomography in Alzheimer's Disease and Other Neurodegenerative Diseases

Jonah Dourson<sup>1</sup>, Tania Turbat<sup>1,2\*</sup>, Keith L. Black<sup>1</sup>, Yusef Koronyo<sup>1</sup>  
and Maya Koronyo-Hamaoui<sup>1,2\*</sup>

The apparent correlations between OCT-structural findings and visual and cognitive functions in AD patients support its utilization in assessing neurodegenerative incidence and progression.

However, while the geometric distribution of progressive tissue atrophy is profound in the superior and inferior quadrants of AD retina, the potential **overlap of the structural changes between various neurodegenerative diseases**, such as PD, HD, and MS may instill **an inherent limitation in differential diagnosis** that should be addressed in future studies

TABLE 2 | Correlations between OCT findings and clinical dysfunction/progression in AD and PD patients.

Clinical diagnosis	Region	OCT type	Degree of correlation <sup>a</sup>	Reference
<b>Correlations</b>				
<b>Alzheimer's disease/mild cognitive impairment</b>				
RNFL thickness vs. cognitive function <sup>b</sup>	All quadrants	sd-OCT, fd-OCT	$r = 0.33$	(43)*, (74, 75)**
	Superior	fd-OCT	$r = 0.24$	(74)*
	Inferior	sd-OCT, fd-OCT	$r = 0.35-0.65$	(53)*, (74)**
	Temporal	NA	NA	NA
	Nasal	NA	NA	NA
GCL-IPL thickness vs. cognitive function <sup>b</sup>	All quadrants	fd-OCT	$r = 0.33-0.49$	(37, 74)*
Macular thickness vs. cognitive function <sup>b</sup>	All quadrants	sd-OCT, fd-OCT	$r = 0.34$	(74)*, (78)**
	Superior	fd-OCT	$r = 0.47$	(38, 41, 75, 82)**
	Inferior	fd-OCT	$r = 0.46$	(74)**
	Temporal	fd-OCT	$r = 0.49$	
	Nasal	fd-OCT	$r = 0.48$	
RNFL thickness vs. visual function	All quadrants	sd-OCT	$r = 0.46-0.76$	(67, 70, 93, 94)*, (79)**
<b>Parkinson's disease</b>				
RNFL thickness vs. disease progression	All quadrants	sd-OCT, stratus-OCT	$r = 0.39-0.66$	(85, 86)*
RNFL thickness vs. visual function	All quadrants	sd-OCT	$r = 0.40$	(86)**

<sup>a</sup>Degrees of correlations are represented as trend to values.

<sup>b</sup>Cognitive function examinations: ADAS-cog, CDR, and MMSE.

\* $p < 0.05$ .

\*\* $p < 0.001$ .

\*\*\* $p < 0.0001$ .

nd, statistical data not shown; nt, a trend, not statistically significant; NA, not applicable; sd-OCT, spectral domain OCT; fd-OCT, frequency domain OCT; ADAS-cog, AD Assessment Scale-cognition; CDR, Clinical Dementia Rating; MMSE, Mini-Mental State Examination.

OCT is likely a biomarker for neurodegenerative diseases.



Be sure to keep up with the future literature regarding OCT and other ocular biomarkers in neurodegenerative disease and other brain insult.

We are a piece of the puzzle, and will have an evolving role in brain insult as more ocular biomarkers are studied.



# YOU WILL SEE PATIENTS WITH BRAIN INSULT

Various presentations

Various etiologies

Various symptoms

Every patient will need a unique management plan

Every patient will need your help (even if it is just reassurance that their visual function / ocular health is good or will improve)

Every patient will be counting on your opinion and guidance

Every patient will be grateful for any help, recommendations, or referrals you can provide!

**YOU are a piece of the brain  
insult puzzle!**

Regardless of how small your  
piece is, it is still vital to your  
patient's prognosis and / or  
quality of life.

Don't underestimate your  
role in diagnosis,  
management and  
rehabilitation of brain insult



**THANK  
YOU!**